

# Treatment of Subungual Myxoma Preserving the Nail Matrix: A Case Report

Leo M. Rozmaryn, MD, Rockville, MD, Arnold M. Schwartz, MD, PhD,  
Washington, D.C.

Subungual myxomas are uncommon, benign, expansile lesions that club the fingertip. Traditionally the nail matrix is incised, which results in permanent nail deformity. This report describes a midlateral approach that not only spares the nail apparatus but demonstrates that the nail can remodel even if a void is left under the nail matrix after excision of the tumor. The histologic examination of the tumor is described. (*J Hand Surg* 1998;23A:178-180. Copyright © 1998 by the American Society for Surgery of the Hand.)

Subungual tumors can cause single-digit clubbing and are unusual benign lesions. They are noninfiltrative expansile masses that round out the nail matrix and plate above and compress the distal phalanx below it.<sup>1</sup> The usual surgical approach is marginal excision.<sup>2</sup>

We present a case of subungual myxoma in a thumb. Previous reports have also focused on its microscopic appearance; however, these have emphasized removal of the nail plate and excision of the tumor through the nail bed with later reconstruction. Typically, permanent nail-bed deformity resulted and was thought to be the normal sequela of treatment.<sup>2</sup> The deformity is primarily due to scarring of the sterile and germinal matrices, which leads to permanent transverse or vertical nail ridging. We propose a midlateral approach. It affords excellent exposure and does not involve the nail apparatus from above but rather skirts it from below allowing full remodeling of the nail plate and bed without deformity.

From The Orthopaedic Center, Rockville, MD, and the Department of Pathology, George Washington University Medical Center, Washington, D.C.

Received for publication Oct. 31, 1996; accepted in revised form May 13, 1997.

No benefits in any form have been received or will be received from a commercial party related directly or indirectly to the subject of this article.

Reprint requests: Leo M. Rozmaryn, MD, The Orthopaedic Center, 9711 Medical Center Drive, Suite 201, Rockville, MD 20850.

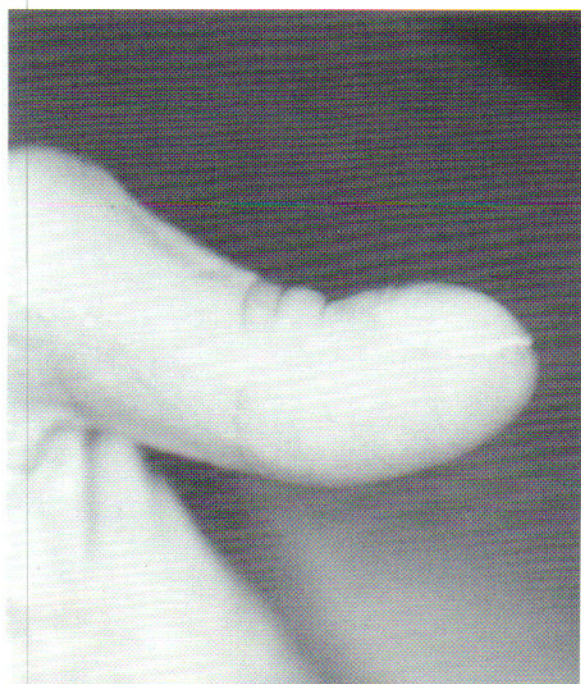Copyright © 1998 by the American Society for Surgery of the Hand.  
0363-5023/98/23A01-0030\$3.00/0

## Case Report

### Presentation and Treatment

A 59-year-old woman presented with a mass in the subungual region of her left thumb for 8 years. It had expanded and rounded the nail and fingertip. There was minimal pain, no drainage, and no recent growth; however, she reported that whenever she sustained even a slight contusion to the thumb, a large subungual hematoma would develop. Examination revealed marked clubbing of the left thumb tip (Fig. 1), normal sensibility, and full interphalangeal joint motion. There was no erythema or fluctuance. Magnetic resonance imaging revealed a 1.5-cm lesion immediately under the nail matrix compressing the distal phalanx, scalloping the dorsal cortex without invasion. The mass was round and hypodense (Fig. 2). Marginal excision was performed through a midradial incision, sparing the overlying nail apparatus (Fig. 3). A plane was established between the tumor and nail matrix above as well as the periosteum below. This required loupe magnification, beaver blades, and an appreciation of the gray/pink boundary between tumor and nail matrix. Although the specimen was encapsulated, it did not separate spontaneously from the nail matrix. In addition, on approaching the tumor, the dissection was straight in rather than angled dorsally to avoid puncturing the matrix at the nail fold. The excised specimen was grossly 2 × 1.5 × 0.5 cm, gray, and rubbery. The



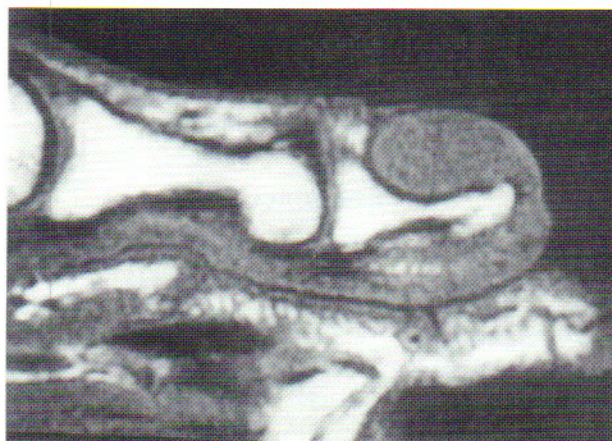


**Figure 1.** Side view of the thumb on presentation. Note the enlargement and rounding of the nail apparatus.

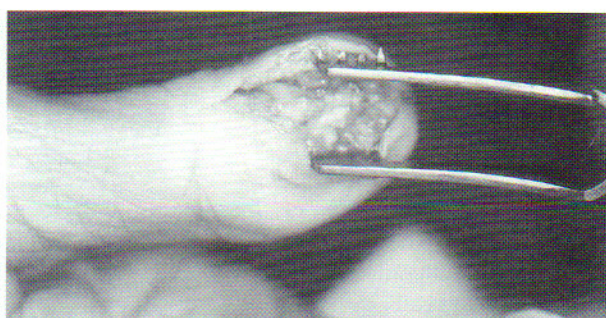
wound was closed, leaving the nail plate and matrix intact. At 8 months, the patient was asymptomatic and her incision had fully healed. Her fingertip and nail had remodeled without deformity (Fig. 4).

#### Pathology

The tumor was a cellular homogeneous proliferation of spindled mesenchymal cells within a promi-

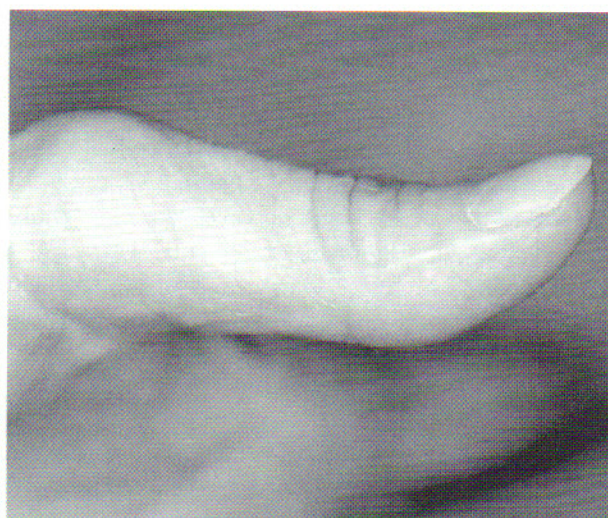

**Figure 2.** Magnetic resonance image of the thumb. The lesion is homogeneous, expansile, and not infiltrative. Note the pressure on the distal phalanx. The nail is not shown.



**Figure 3.** Intraoperative view of the thumb. A midlatero-radial approach is used so that the tumor can be completely visualized.

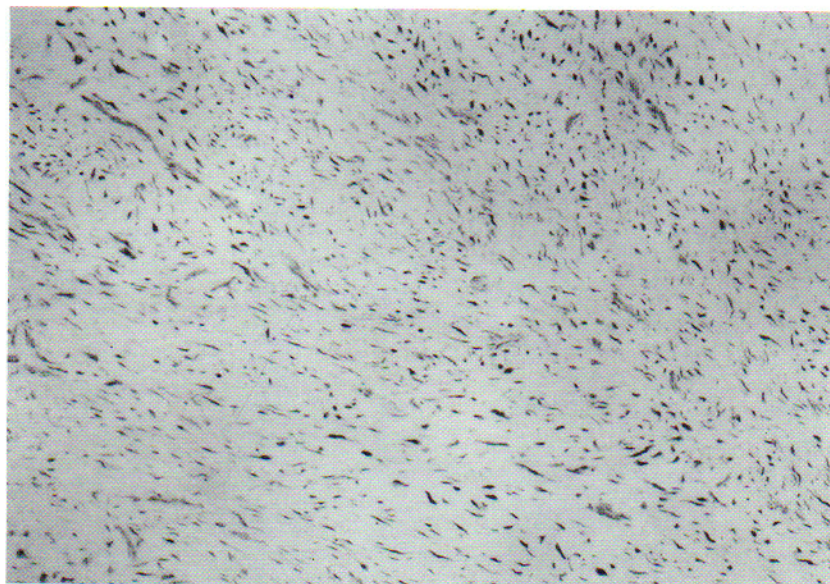
nent, poorly vascularized myxoid matrix (Fig. 5 that grew with a "pushing" margin adjacent to the host fibrovascular tissue. No evidence of nuclear atypia, mitotic activity, or tumor necrosis was identified. The spindled cells had features of myxoid cells with benign-appearing nuclei containing even chromatin and tapered cytoplasm, separated by a wavy matrix material. The differential diagnosis included myxoid, chondroid, neural, fibrous, and epithelial tumors. The lack of nuclear pleomorphism and high-grade cytologic features and the absence of tumor hemorrhage and necrosis ruled out a malignant process. The characteristic mesenchymal organization, the absence of a lacunar pattern, and the wavy matrix eliminated the possibility of a chondroid differenti-



**Figure 4.** Side view of the thumb at a follow-up examination 8 months after surgery. Note the complete remodeling of the nail apparatus and the healed surgical site.



**Figure 5.** Histopathology of the subungual mass. The tumor is a homogeneous proliferation of mesenchymal spindled cells with abundant matrix. Note the absence of chondroid differentiation (original magnification,  $\times 100$ ).



ated tumor. So that we could better characterize the tumor, histochemical and immunohistochemical staining were performed. The absence of S-100 reactivity and the lack of an appropriate matrix precluded a diagnosis of neurofibroma. The absence of keratin staining and the prominent matrix eliminated a diagnosis of spindled epithelial tumor. The final diagnosis of a benign myxoma was based on the characteristic mesenchymal pattern, the delicate reticulin-positive matrix, the reactivity to vimentin, and the absence of markers (S-100 and keratin) typically positive for other tumors.

### Discussion

Myxomas are benign lesions that are quite uncommon but usually occur in striated or heart muscle.<sup>3</sup> Bone myxomas have been recorded as well and have been associated with fibrous dysplasia.<sup>4</sup> Myxomas of the soft tissues of the hand, however, are rare. Those in the subungual region are rarer still, with only 4 cases reported to date.<sup>1,2</sup> These masses are soft and mucoid, have a unicentric origin, grow by expansion, and do not metastasize.<sup>5</sup> Their cellular origin is unclear, so they are called by some "tumors of uncertain histogenesis."<sup>1</sup>

The surgical approach we used was versatile and utilitarian. It afforded a complete, clear view of the lesion and allowed a full marginal excision. Through it, the distal phalanx could be seen in its entirety and could be inspected for possible infil-

tration of the tumor. This approach may be considered for all noninvasive space-occupying subungual lesions, regardless of type. If the lesion is encapsulated, it is not difficult to establish a plane between the lesion and the nail matrix above; however, care must be taken to not lacerate the nail matrix. Closure of the lateral approach is straightforward compared to that of the traditional trans-nail matrix technique, in which the surgeon is faced with repairing or reconstructing the nail matrix after the lesion has been excised. Our initial concern about closing the wound with a large empty space under the nail bed proved groundless, as the presence of the intact nail plate above splinted the nail matrix and prevented its collapse. Apparently, the space filled with fibrous tissue, allowing the nail apparatus and the fingertip to remodel over the following 6 months.

### References

1. Hill TL, Jones BE, Park KH. Myxoma of the skin of a finger. *J Am Acad Dermatol* 1990;22:343-345.
2. Kaehr D, Klug MS. Subungual myxoma. *J Hand Surg* 1986;11A:73-76.
3. Winke BM, Blair WF, Benda JA. Myxomas in the fingertips. *Clin Orthop* 1988;237:271-274.
4. Blasier RD, Ryan JR, Schaldenbrand MF. Multiple myxomata of soft tissue associated with polyostotic fibrous dysplasia: a case report. *Clin Orthop* 1986;211-214.
5. Stout AP. Myxoma, the tumor of primitive mesenchyme. *Ann Surg* 1948;127:706-719.