

Seventh edition

A Manual of Orthopaedic Terminology



Fred R.T. Nelson, MD, FAAOS

Director Research and Education

Director Osteoarthritis Center

Orthopaedics

Hentry Ford Hospital


Detroit, Michigan

Carolyn Taliaferro Blauvelt

Formerly Writer-Editor, Medical-Dental Publications

National Naval Medical Center

Bethesda, Maryland



Acknowledgments

For contributions to the last six editions, we wish to acknowledge Alan D. Aaron, MD, The American Occupational Therapy Association, Rockville, MD; The American Physical Therapy Association, Alexandria, VA; Norman Berger, CP; Mark A. Berman, CO; CE Brooks, MD, FRCS(C); Wilton H. Bunch, MD, PhD; John F. Burkart, MD; Robert W. Chambers, MD; David Collon, MD; Joseph Craig, MB, ChB; Helen F. Delaney, OT; J.M. Dennis, DPM; Charles M. Dilla, PT, PA; Terry Elan, Prosthetist; Charles H. Epps, Jr., MD; David Fessell, MD; Jean Flint, Orthotist; Gary E. Friedlaender, MD; David P. Fyhrrie, PhD; John J. Gartland, MD; Joshua Gerbert, DPM, MS; Stephen B. Gunther, MD; Stephen F. Gunther, MD, FAAOS; Carole Hays, MA, OTR, FAOTA; Donald L. Hiltz, PT; Donald P. Jenkins, PhD; Emily Jeter, OTR/L; James H. Kimura, PhD; Steve Kramer, CPO; David M. Lichtman, MD, FACS; Frederick G. Lippert, III, MD; Donna M. Mathisen, GPT; W. Patrick Monaghan, PhD; Francesca C. Music, MS, MT; Thomas Neviasser, MD; Jeffrey M. Ogorzalek, MD; Nyana Parikh, BS, Eric L. Radin, MD; Lee H.

Riley, III, MD; Leo M. Rozmaryn, MD, FAAOS; James M. Salander, MD, FACS; Barton K. Slemmons, MD, FAAOS; Jeff Virgo, OTC, OPA-C, RSA; Samuel Wiesel, MD; David Q. Wilson, MD, FAAOS; Kent Wu, MD; William D. Wurzel, MHA, MD; and Kae S. Yingling, MD.

We wish to remember the late Charles V. Heck, MD, the former executive director of the American Academy of Orthopaedic Surgeons, who, through his support and encouragement, helped to launch this manual as a supplemental reference for the field of orthopaedics.

The success of the first six editions proved the need for a reference of this kind for this specialty. It is with pleasure that we present this seventh edition with many, many thanks not only to our contributors, but also to the editorial staff and those "behind the scenes" at Elsevier and Mosby, Inc., whose continued guidance, support, and publication skills have contributed much to the book's success.

Fred R. T. Nelson
Carolyn Taliaferro Blauvelt

Contributors

No one can write a book on all areas of orthopaedics and keep it current without the help of many competent people. This manual is no exception. We have chosen contributors whose background and experience make them well qualified to assist in updating material for each edition and who work directly or indirectly in this specialty. These people have generously given their time, in view of other professional commitments, to improve the correctness and accuracy of information, provide an update, and give constructive criticism. We can share in the success of this manual with them, and we wish to express our appreciation and thanks to our past contributors, and the following persons and organizations who participated in the revisions of the sixth edition.

Classifications of Fractures, Dislocations, and Sports-Related Injuries

Paul J. Dougherty, MD
Chief, Orthopaedic Trauma Division
Orthopaedic Surgery Residency Program Director
Department of Orthopaedic Surgery
Henry Ford Hospital
Detroit, Michigan

Musculoskeletal Diseases and Related Terms

Audrey Austin, MD
Assistant Professor of Pediatrics
Children's National Medical Center
Washington, DC

Patricia A. Kolowich, MD
Division Head, Center for Athletic Medicine
Department of Orthopaedics
Henry Ford Hospital
Detroit, Michigan

James M. Salander, MD, FACS
Associate Professor of Surgery
Uniformed Services University of the Health Sciences
Bethesda, Maryland

Susan A. Scherl, MD
Associate Professor
Department of Orthopaedics
The University of Nebraska
Omaha, Nebraska

Imaging Techniques

Joseph Craig, MB, ChB
Staff Radiologist, Department of Radiology
Henry Ford Hospital
Detroit, Michigan

Marnix T. van Holsbeeck, MD
Professor, Department of Radiology
Wayne State Medical School
Director, ER and Musculoskeletal Radiology
Department of Radiology
Henry Ford Health System
Detroit, Michigan

Orthopaedic Tests, Signs, and Maneuvers

Patricia A. Kolowich, MD
Division Head, Center for Athletic Medicine
Department of Orthopaedics
Henry Ford Hospital
Detroit, Michigan

Laboratory Evaluations

Timothy C. Sorrells, MD
Assistant Professor of Pathology
Department of Pathology
Uniformed Services University of the Health Sciences
Captain, Medical Corps U.S. Navy
Head Laboratory Department
National Naval Medical Center
Bethesda, Maryland

Corey Jenkins, MS, MT(ASCP)SBB
Department Head
Armed Services Blood Bank Center
National Naval Medical Center
Bethesda, Maryland

Casts, Splints, Traction, and Dressings

Colleen Ann Collins, COT
Orthopedic Technician
Orthopedics Henry Ford Medical Center,
Fairlane
Dearborn, Michigan

Anatomy and Orthopaedic Surgery

Craig D. Silvertown, DO
Associate Professor, Department of Orthopaedics
Rush Medical University
Chicago, Illinois
Chief of Adult Reconstructive Surgery
Department of Orthopaedics
Henry Ford Hospital
Detroit, Michigan
Senior Staff Surgeon
Wilford Hall Medical Center (USAF)
San Antonio, Texas

The Spine

Rahul Vaidya, MD, CM, FRCSc

Chief of Orthopaedic Surgery
Department of Surgery Detroit Receiving Hospital
Detroit, Michigan

The Hand and Wrist

Leo M. Rozmaryn, MD
Assistant Adjunct Professor of Surgery
Department of Orthopaedics
Uniformed Services University Health Science Center
Bethesda, Maryland
Chief Department of Orthopaedics
Shady Grove Adventist Hospital
Rockville, Maryland

The Foot and Ankle

David A. Katcherian, MD
Foot and Ankle Division Head,
Orthopaedic Surgery
Henry Ford Hospital Detroit, Michigan

Physical Medicine and Rehabilitation: Physical Therapy and Occupational Therapy

Amanda Lane Calhoon, MSOT, OTR/L
Occupational Therapist
Hand and Upper Extremity Rehabilitation
Shady Grove Center for Sports Medicine and
Rehabilitation
Rockville, Maryland

Introduction: The Research Enterprise

Clifford M. Les, DVM, PhD, MRCVS
Associate Professor, Anatomy and Cell Biology
School of Medicine, Wayne State University
Senior Staff Scientist; Head of the Anatomy Section
Bone and Joint Center
Henry Ford Hospital Detroit, Michigan
Affiliate Faculty Clinical Science, College of Veterinary
Medicine and Biomedical Sciences
Colorado State University Ft. Collins, Colorado

ICD Codes For Eponymic Musculoskeletal Disease Terms

M. Suzanne DeMan, CPC, CPC-H, CCP
Coding Audit Specialist
Department of Orthopaedic Trauma
Detroit Receiving Hospital
Detroit, Michigan

Or''tho-p
vention
children)
meaning
correct o
child.

The
treatmen
with mus
cles, join
sels, ner
nonsurgi
of these
ities, me
patholog
few cond
dic speci
rehabilita
care and

The o
culoskele
orthopae
addition,
neurolog
neering i
expertise
graphy,
magnetic
edge of
fixation
changing

The Hand and Wrist

Where is there available a precision instrument that can either gently pick up eggs or lift 200 lb; detect the weight of only four grains of sand, temperature differences of 1 degree, and the distance between two points less than 0.1 inch; be remote controlled, self-powered, and transportable to any part of the world? This priceless tool is available at no cost to almost all humankind—the hand.

A description of the intricate anatomic features of the hand and wrist is presented with illustrations. The sequence of definitions given here will help to define the basics of hand control, kinematics, and function. The chapter reflects changes in the anatomy format, with an explanation of zones, pulleys, and other miscellaneous names specific to the hand.

There are many abbreviations used in hand anatomy because of the lengthy Latin names, for example, flexor pollicis longus (FPL) tendon or metacarpophalangeal (MCP) joint. Usually the Latin name is spelled out initially and abbreviated subsequently. Appendix A (Orthopaedic Abbreviations) lists the many hand abbreviations used to simplify the terminology.

Anatomy of the Hand and Wrist

Bones (Fig. 10-1)

accessory bone: an extra bone that may develop in the carpus of the wrist as seen on radiographs; an anomaly.

carpal bones: the eight bones of the anatomic wrist, arranged in a proximal and distal row, and held firmly together by ligaments. The proximal row from lateral to medial (radial to ulnar) includes the **scaphoid** (navicular), **lunate** (semilunar), **triquetrum** (triangular), and **pisiform**. The distal row leading from the thumb side is composed of the **trapezium** (greater multangular), **trapezoid** (lesser multangular), **capitate**, and **hamate**.

carpus: the wrist; term applied to the structures of the wrist including the carpal bones.

DRUJ (distal radial ulnar joint): acronym commonly used to describe that joint (pronounced “drudge”).

fossae (fossa, sing.): the scaphoid and lunate fossae are normal recesses in the articular surface of the distal radius that allow articulation of the scaphoid and lunate, respectively.

metacarpals: the five long bones of the hand in the palm area. The bases of the metacarpal bones articulate proximally with the distal row of carpal bones.

phalanges: the bones of the thumb and fingers. Each phalanx has a body, proximal base, and distal head. There are two phalanges in the thumb (proximal and distal) and three phalanges in each of the four digits (proximal, medial, and distal).

sesamoids: small bones on the medial and lateral side of the base of the proximal phalanx of the thumb (metacarpophalangeal [MCP] joint). The sesamoids articulate with the head of the metacarpal bone to

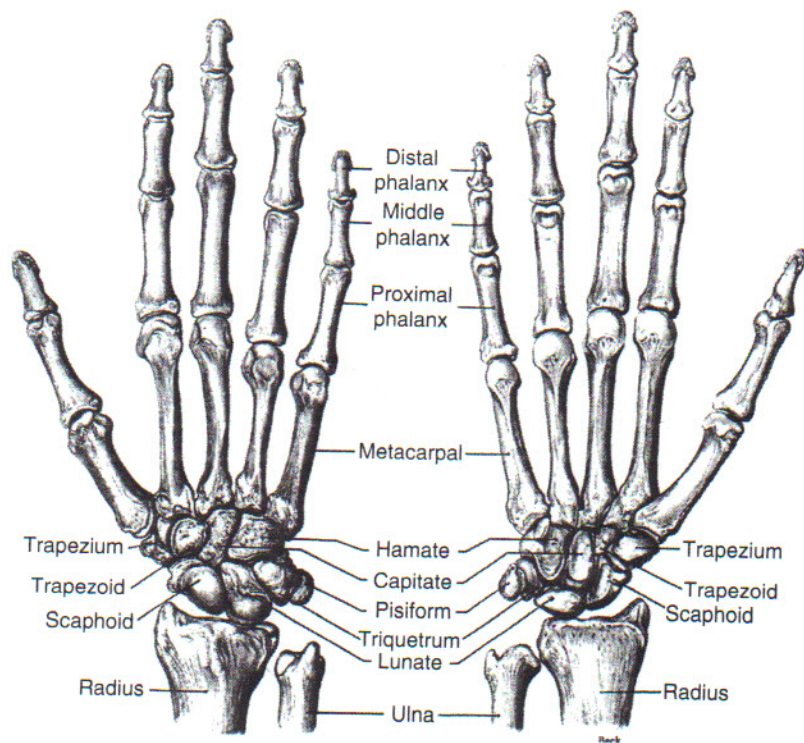


FIG 10-1 Bones of the right hand and wrist, dorsal surface. (From Anthony C, Kolthoff N: *Textbook of Anatomy and Physiology*, ed 9, St Louis, 1975, Mosby.)

which muscles are attached. A sesamoid bone may also be found on the lateral side of the MCP joint of the index finger and medial side of the MCP joint of the little finger.

sigmoid notch: the articular surface on the distal radius that accepts the ulna in the distal radioulnar joint.

styloids: bony protuberances off the radius and ulna that act as attachment sites for the radial and ulnar collateral ligaments, respectively. The ulna styloid is also an attachment for the triangular fibrocartilage complex.

tubercles: bony prominences that provide ligamentous attachment. In the hand, these include the scaphoid, trapezium, Lister tubercle, and the hook of the hamate.

tuft: the terminal bony expansion of the distal phalanx.

Joints

The joints of the hand are remarkable for the variability of motion that supports the fingers and thumbs in many tasks (e.g., the carpometacarpal [CMC] joint of

the thumb can move in all planes). The joints of the phalanges are the proximal, medial, and distal joints and are referred to as follows:

Carpometacarpal (CMC)
Distal interphalangeal (DIP)
Metacarpophalangeal (MCP)
Midcarpal (MC)
Proximal interphalangeal (PIP)
Radiocarpal (RC)

volar plate: a thickening of the joint capsule of the volar aspect of the MP and IP joints that prevent hyperextension of these joints. Proximally, these begin with the "check-rein" ligaments.

Muscles

There are large muscles in the forearm that insert into the bones of the hand by means of their tendons (Figs. 10-2 and 10-3). These **extrinsic muscles** cause the hand and

Branch c
to
Op
e:
adduct

A
(tri

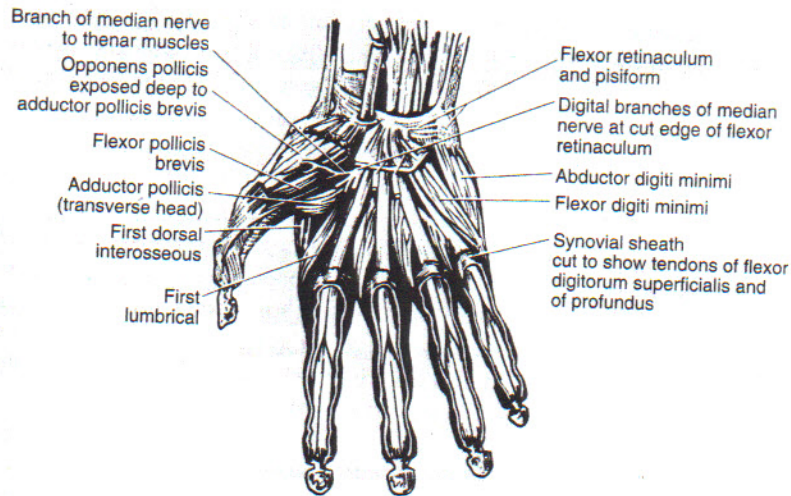


FIG 10-2 Muscles of the anterior aspect of the human hand; the palmar aponeurosis has been removed. (From DiDio LJA: *Synopsis of Anatomy*, St Louis, 1970, Mosby.)

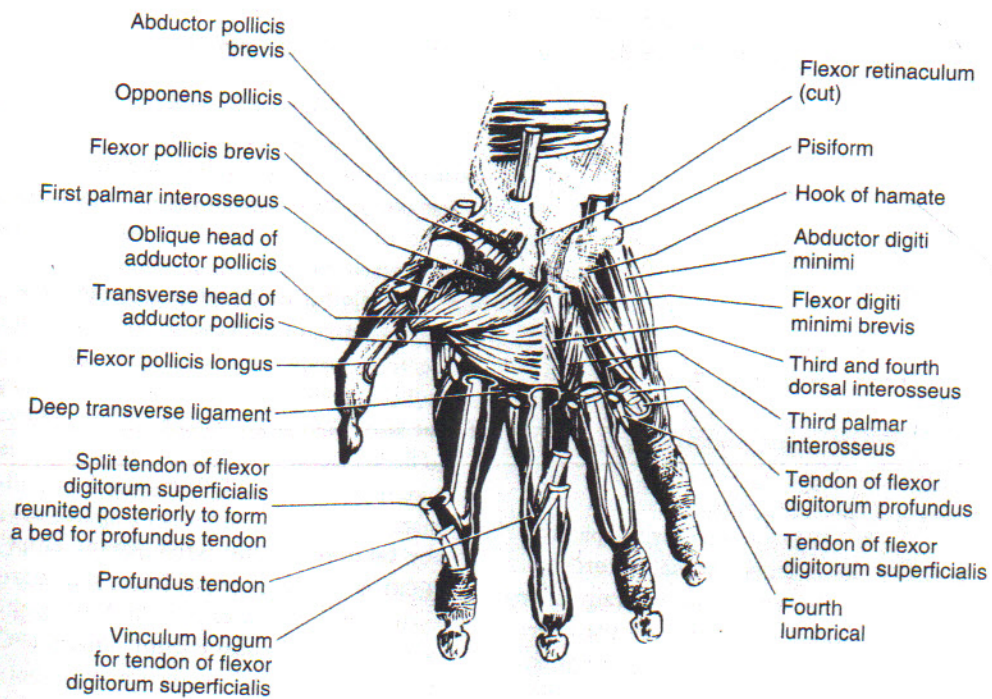


FIG 10-3 Muscles of the anterior aspect of the human hand. (From DiDio LJA: *Synopsis of Anatomy*, St Louis, 1970, Mosby.)

fingers to flex and extend (close and open). The **intrinsic muscles** are small and originate within the hand. These control positioning and to a large extent functional coordination of the fingers. In normal hand function, all these groups work together in intricate unison.

Extrinsic Muscle Function

wrist flexors: flexor carpi ulnaris (FCU), palmaris longus (PL), flexor carpi radialis (FCR); insert on the metacarpals, carpal bones, and ligaments. They cause strong wrist flexion.

wrist extensors: extensor carpi radialis longus (ECRL), extensor carpi radialis brevis (ECRB), extensor carpi ulnaris (ECU); insert on the metacarpals.

finger flexors: flexor digitorum profundus (FDP), flexor digitorum sublimis or superficialis (FDS), flexor pollicis longus (FPL) (thumb); insert on either the distal or the middle phalanges of the digits and cause powerful finger or thumb flexion.

finger extensors: extensor digiti quinti proprius (EDQP), extensor digitorum communis (EDC), extensor indicis proprius (EIP); insert on the bones and extensor hoods of the fingers and cause extension of the digits.

thumb extensors: extensor pollicis longus (EPL) and brevis (EPB).

thumb abductors: abductor pollicis longus (APL) and brevis (APB).

thumb adductors: extensor pollicis longus (EPL) and adductor pollicis (add poll).

Intrinsic Muscle Function

hypothener muscles: **opponens digiti quinti** (or **minimi**) (ODQ/ODM), **flexor digiti quinti brevis** (FDQB), **abductor digiti quinti** (or **minimi**) (ADQ/ADM); a less important group of intrinsic muscles that arise from the carpal bones and insert on the little finger, metacarpal, and proximal phalanx.

intrinsic muscles: **lumbricals**, **dorsal interossei**, **volar interossei**; arise from the metacarpals or from the flexor tendons and insert into the finger dorsal (extensor) mechanism and base of the proximal finger bone. They are responsible for spreading and bringing together the fingers and for firm coordination of motion at each finger joint.

thenar muscles: **opponens pollicis** (OP), **abductor pollicis brevis** (APB), **flexor pollicis brevis** (FPB) deep and superficial head, the deep head sometimes called first palmar interosseous (intrinsic muscles of the thumb); arise from the carpal bones and ligaments at the base of the palm and insert on the proximal phalanx or on the thumb metacarpal. They function to bring the thumb out and away from the palm and to oppose it to the other fingers. One intrinsic muscle arises from the metacarpals and crosses deep in the palm to the thumb. This adductor pollicis muscle pulls the thumb forcefully back in toward the palm (adduction).

Associated Forearm Muscles and Tendons

other muscles in the forearm: brachioradialis, pronator teres (PT), supinator, anconeus, and pronator quadratus (PQ); these do not extend to the hand but affect the position of the hand by actions such as rotation of the forearm (pronation and supination).

aponeurosis: term usually used to denote the whitish or silvery thick membranes that separate muscles, but in the hand is a description of the entire extensor apparatus of the digits distal to the metacarpophalangeal joint to its insertion on the proximal end of the distal phalanx.

extensor carpi radialis intermedius: an anatomic variant (a third radial wrist extensor) that can be used to restore thumb function in paralytic disorders when present.

extensor digitorum brevis manus muscle: an anatomic variant of the extensor indicis proprius muscle originating from the dorsal lip of the distal radius inserting on the extensor indicis proprius.

flexor wad of five: five muscles with a common origin in the medial elbow: pronator teres (PT), flexor digitorum profundus (FDP) and sublimis (FDS), palmaris longus (PL), and flexor carpi radialis (FCR).

flexor tendons of the wrist: **flexor carpi radialis** (FCR) is the radial wrist flexor that travels in its own tunnel and inserts at the base of the second metacarpal. The **flexor carpi ulnaris** (FCU) (the ulnar wrist flexor) is the more important and powerful. It has a primary insertion on the pisiform but will send fibers distally to intermesh with the

hy
syn
tui
radia
on
in
pro
dig
po
retina
tui
pu

Zones
A surg
gers, l
impor
each z
ferent
zones
cits wi

zone
ins
tio
of t
zone
tur
pul
Cal

zone I
rica
pal
zone I
zone V
pal

Pulley.
Pulleys
that he
or cruc

hypothenar muscle fascia. These tendons, with a synovial lining, glide back and forth through the tunnel as the fingers and wrist are moved.

radial sagittal bands: transverse tendinous structures on the radial side of the central extensor tendon slip in the region of the metacarpophalangeal joint to prevent ulnar subluxation of the extensor digitorum communis with flexion of the metacarpophalangeal joint.

retinacular ligament: fibrous bands that cover tendon tunnels such as extensor retinaculum and flexor pulleys.

Zones

A surgical zone system has been established for the fingers, hand, wrist, and forearm. The anatomic zones are important in determining technical considerations for each zone, surgical approaches, and corrections for different disorders. The clinical importance of anatomic zones is that, if an area is left unrepaired, specific deficits will occur in the extensor or flexor tendon zones.

zone I: from flexor digitorum profundus (FDP) insertion to flexor digitorum sublimis (FDS) insertion, anatomic structures found distal to the insertion of the sublimis tendon into the middle phalanx.

zone II: called "no man's land," the anatomic structures found in the region just proximal to the A1 pulley up to zone I.

Camper chiasm: a bifurcation of the flexor digitorum sublimis (FDS) in zone II that allows passage of the flexor digitorum profundus (FDP) through it. This occurs just proximal to the insertion of the flexor digitorum sublimis (FDS) in the middle phalanx; **chiasma tendinum**.

zone III: anatomic structures at the origin of the lumbricals in the region of the arterial arch, from the carpal tunnel to zone II.

zone IV: the carpal tunnel.

zone V: anatomic area of the wrist proximal to the carpal tunnel.

Pulleys

Pulleys are thickened portions of flexor tendon sheaths that hold tendons in place. They are labeled as annular or cruciate, depending on the orientation of the fibers

of the pulley. The most proximal pulley is located on the distal metacarpal and is labeled annular 1 (A1) and then annular 2 through 4. The cruciate pulleys are similarly labeled C1 through C3 (Fig. 10-4).

A1	zone II	C1	zone II
A2	zone II	C2	zone I
A3	zone II	C3	zone I
A4	zone I	A0	zone IV (palmar fascia)

Ligaments and Fascia

There are numerous ligaments named for the bones to which the ligaments are attached.

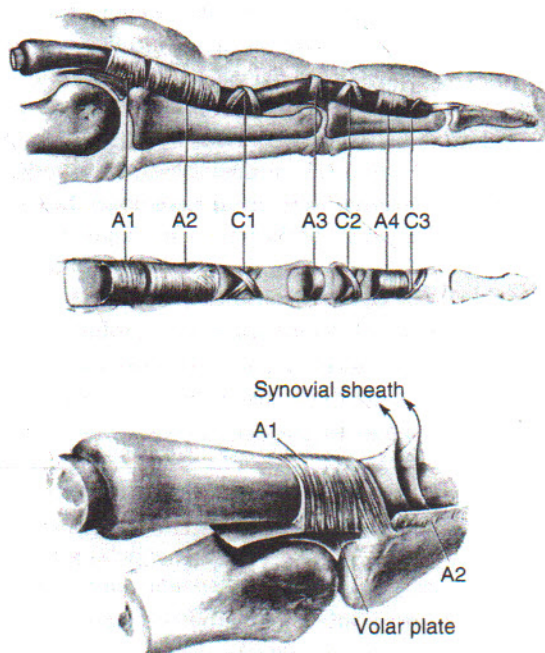


FIG 10-4 This anatomic diagram of various parts of flexor sheath is helpful in understanding gliding of tendon. Maintenance of second annulus (A2) and fourth annulus (A4) is essential to retain appropriate angle of approach and prevent "bowstringing" of flexor tendons or tendon graft. (From Doyle JR, Blythe W: In American Academy of Orthopaedic Surgeons: Symposium on Tendon Surgery in the Hand, St Louis, 1975, Mosby.)

deep transverse metacarpal I.: specific distal ligaments between the second, third, fourth, and fifth metacarpophalangeal (MCP) volar plates.

juncturae tendinum: tendinous interconnection between extrinsic extensors over the dorsum of the hand. These allow synchronized digital extension; **connexus intertendineus**.

transverse carpal I.: the strong ligamentous band that lies across the arch of the carpal bones forming the roof of the carpal tunnel. It covers the median nerve and binds down the nine long flexor tendons of the thumb and fingers.

triangular I.: interconnecting fibers that join the two lateral bands dorsally and hold them in place. They are located over the proximal end of the middle phalanx just distal to the insertion of the central slip of the extensor tendon; **triangular fibrocartilage complex**.

vincula longa and breva: vascular and fibrous connections from the floor of the flexor tunnel to each of the two flexor tendons. The vincula breva lie close to the tendon insertions.

volar carpal I.: the ligament that spans and covers the median nerve and canal of Guyon and runs from the transverse carpal ligament radially to the hypothenar fascia ulnarly. This ligament binds down the nine long flexor tendons of the thumb and fingers.

Extrinsic Wrist Ligaments

dorsal radiocarpal I.: (radiolunatotriquetrum).

volar I.: deep radioscaphocapitate, long radioscapholunate, short radioscapholunate, and radiolunate and ulnar lunate.

Intrinsic Wrist Ligaments

arcuate (deltoid) I.: a major stabilizer of the midcarpal joint; ulnar arm (triquetrocapitate I.), radial arm (distal to scaphocapitate I.).

deep transverse intermetacarpal I.: fibrous interconnections between metacarpal heads II through V.

intermediate I.: lunatotriquetrum, scapholunate, and scaphotrapezium.

long I.: volar intercarpal ("U," deltoid arcuate).

short I.: interosseous.

space of Poirer: a weak area of the midcarpal joint, that is, the arcuate ligament volar and distal to the

lunate because the capitulunate I. is either absent or attenuated.

superficial transverse intermetacarpal I.: the expansion of the palmar fascia in the region of the distal metacarpals; **natatory I.**

Collateral Ligaments

The collateral ligaments of the elbow and wrist are supportive ligaments providing stability on the medial and lateral side of the wrist joint.

radial collateral I.: scaphocapitate I. (radial arm).

ulnar collateral I.: triquetrocipitate I. (ulnar arm).

Digital Collateral Ligaments

accessory I.: originates volar and deep to the main collateral ligaments and runs to the volar plate.

beak ligaments: volar ulnar ligaments that stabilize the carpometacarpal joint of the thumb; originates on the volar aspect of the triscaphe joint and inserts on the volar ulnar surface of the proximal thumb metacarpal.

dorsal extensor compartments: the six fascial compartments on the dorsum of the distal radius for the wrist extensors numbering from radial to ulnar; these are defined by extensor retinacular tunnels over the wrist.

I: abductor pollicis longus (APL) and extensor pollicis brevis (EPB).

II: extensor carpi radialis longus (ECRL) and brevis (ECRB).

III: extensor pollicis longus (EPL).

IV: extensor indicis proprius (EIP) and extensor digitorum communis (EDC) II-V.

V: extensor digiti minimi (EDM) or quinti (EDQ).

VI: extensor carpi ulnaris (ECU).

main I.: runs from the center of rotation of the metacarpal or phalangeal head to the proximal metaphyseal flair of the phalanx adjoining.

Palm

Palmar Fascial Compartments

flexor and extensor retinacula: special thickening of deep fascia where muscles of forearm become tendons and pass into the hand into a broad band of superficial fascia over the dorsum of the wrist; help to restrain the extensor tendons and prevent tendons from bowstringing away from wrist.

digital

ger 1

hypothen

sic mus

hypothen

metacar

the the

Kanavel s

thenar

flexor t

Landsme

of the f

the two

midpalma

from th

natatory I

interme

palmar fa

of the

palmar

structu

palmar sk

natural

palmar

and th

The d

middle

septa: tw

mar ap

and hy

thenar er

muscle

thenar sq

of the

web I.: e

base of

Bursa

All bursa

vium). Fo

interr

call;

flex

radial

(FP

digital retinaculum: the covering fascia of the finger flexors.

hypothenar eminence: prominence caused by intrinsic muscle mass on little finger side of the palm.

hypothenar space: deep space overlying the fifth metacarpal that may or may not be connected to the thenar space proximally.

Kanavel spaces: two fascial spaces of the palm, one thenar and one midpalmar, lying deep to the long flexor tendons and separated by a septum.

Landsmeer I.: fibrous tissue bands on the lateral side of the fingers that help to synchronize the motion of the two distal joints; **oblique retinacular ligaments.**

midpalmar space: a deep potential space that runs from the third to fifth ray.

natatory I.: another name for the superficial transverse intermetacarpal I.

palmar fascia: complex interwoven fascia in the palm of the hand that is a part of the expansion of the palmaris longus (PL) and protects the delicate structures in the hand.

palmar skin crease: the creases in the palm caused by natural folds in the skin. These are labeled as distal palmar crease (DPC), midpalmar crease (MPC), and thenar palmar crease (TPC), the "life line." The digital skin creases are labeled proximal, middle, and distal.

septa: two fibrous septa pass deeply from sides of palmar aponeurosis and separate muscles of the thenar and hypothenar deep spaces from midpalmar space.

thenar eminence: the prominence caused by intrinsic muscle mass on the thumb side of the palm.

thenar space: the potential space on the thumb side of the hand deep to the tendons and nerves.

web I.: expansion of the palmar fascia between the base of the fingers.

Bursa

All bursa are lined with synovial sheaths (tenosynovium). Following are the important ones in the hand.

intermediate bursa: occasionally seen anatomically as the bursa containing the index finger flexor tendon sheath.

radial bursa: sac containing the flexor pollicis longus (EPL) tendon sheath in the palm and thumb.

ulnar bursa: sac in the palm containing tendon sheaths of the index, long, ring, and little fingers and extending to the end of the little finger.

Miscellaneous

anatomic snuff box: the area of the lateral wrist formed between the extensor pollicis longus (EPL) tendon medially, and abductor pollicis longus (APL) and extensor pollicis brevis (EPB) tendons laterally. With the thumb abducted and extended, a triangular depression is made on the dorsum of the wrist at the radial border.

arcade of Frohse: tunnel through supinator muscle for the deep radial nerve; anatomic series of arches.

carpal tunnel: space in the wrist created by the volar carpal ligament. This space contains the flexor tendons of the fingers and thumb, as well as the median nerve.

Guyon canal: space between the hamate and pisiform bones at the wrist for the ulnar artery and nerve, covered by the ulnar side of the volar carpal ligament. Floor is the pisohamate ligament.

hook of hamate: bony prominence (tubercle) that provides ligamentous attachment.

ligamentum subcruentum: the loose richly vascularized connective tissue that sits near the ulnar styloid in between the limbs of the distal radial ulnar joint ligament.

Lister tubercle: bony prominence on the distal dorsal radius for ligamentous attachment.

radial lunate angle: an angle created by the line perpendicular to the line connecting the distal tips of the lunate on the lateral x-ray with the long axis of the radius. This is used to estimate dorsal intercalated segment instability (DISI) and volar intercalated segment instability (VISI) deformities in wrist injuries.

slider crank mechanism: an engineering model of scaphoid motion in carpal kinematics.

The Fingers

central slip (tendon): the portion of the extensor tendon that inserts into the middle phalanx.

cutaneous I.: ligaments that restrain the skin during finger motion and include the following:

Cleland I.: fibrous tissue bands on the lateral side of the fingers that stabilize the skin during finger movement, dorsal to Grayson I.

Grayson I.: fibrous tissue bands of the finger extending from the volar distal interphalangeal (DIP) and proximal interphalangeal (PIP) joints to the lateral skin.

distal pulp: the mass of tissue of the volar distal finger. It is the soft cushion of the palmar surface of the distal phalanx.

dorsal expansion: the fibers spreading laterally at the base of the dorsal hood.

extensor hood: the fan-like expansion of the extensor communis tendon over the dorsum and sides of the *metacarpophalangeal* (MCP) joints. This complex structure brings together intrinsic and extrinsic tendons to control interphalangeal (IP) joint extension and metaphalangeal (MP) joint flexion or extension.

interdigital commissure: floor of the webspace between two digits, which follow a very specific anatomic pattern and must be carefully reconstructed in syndactyly surgery.

knuckle pad: the thick skin over the dorsum of the distal interphalangeal (DIP) and proximal interphalangeal (PIP) joints of the finger.

lateral bands: the portions of the intrinsic muscle tendons that run laterally across the proximal phalanx to the dorsum of the distal interphalangeal (DIP) and proximal interphalangeal (PIP) joints.

septa: fibrous tissue structures in fat pad of the fingertips.

skin creases: indentations in the skin at the point of natural motion points of the finger. The digital skin creases are labeled proximal, medial, and distal.

webspace: the skin web area between the base of the fingers.

The Nail

cuticle: the skin edge immediately covering the base of the fingernail.

eponychium: thin skin covering (epidermis) at the base of the nails on the dorsal surface; **cuticle**.

germinal matrix: the cells that generate the tissues that eventually form the nail from the base of the nail; primitive stage of development.

hyponychium: the thickened epidermis immediately under the distal portion of the nail; **subungual tissue**.

lunula: the white crescentic (half-moon shaped) area at the base of the nail.

nail matrix: the proximal portion of the nail bed from which growth mainly proceeds; also, the tissue on which the deep aspect of the nail rests; **matrix unguis, nail bed**.

nail plate: the hard plate of the distal end of the dorsum of the fingers and thumbs. This rigid outer covering extends approximately 8 mm under the nail fold (perionychium) and arises from the nail bed (matrix unguis).

paronychium: a fold of skin (nail folds) that surrounds the nail at the base; the epidermis bordering the nail; **perionychium**.

subungual space: the potential space between the nail and nail bed; common site for a hematoma.

unguis: the horny cutaneous plate on the dorsal surface of the distal end of a finger; the **nail**.

Nerves and Arteries

antebrachial cutaneous nerve: medial/lateral and sensory to the thumb.

axolemma: a column of neuronal cytoplasm enclosed by cell membrane including cell body, dendrites, and the axon.

common digital arteries and nerves (Fig. 10-5): the main branch of the various nerves or arteries in the palm; these then divide into the proper digital arteries and nerves.

dorsal digital artery and nerve: common and proper, the branches of artery and nerve in the dorsum of the finger.

intercompartmental supraretinacular arteries: these are series of arteries that branch off of the radial artery and supply the dorsal aspect of the distal radius and are described by the relationship to the extensor compartment of the wrist and the extensor retinaculum. These are generally fairly superficial in nature, and are used in the formation of vascularized pedicle-based bone grafts.

intercostal nerves: an array of nerves that run between the ribs and are occasionally used in brachial plexus reconstruction.

FIG 10-5 Ma
Guyon canal.

interscale

anterio
the mi
This sp
and br:

lateral ci
provide
metaca

Martin-Gr

mediar
that nc
brachia
the mi
that co

median n
the ha
under
of the s
nens, t

ANTERIOR (PALMAR) VIEW

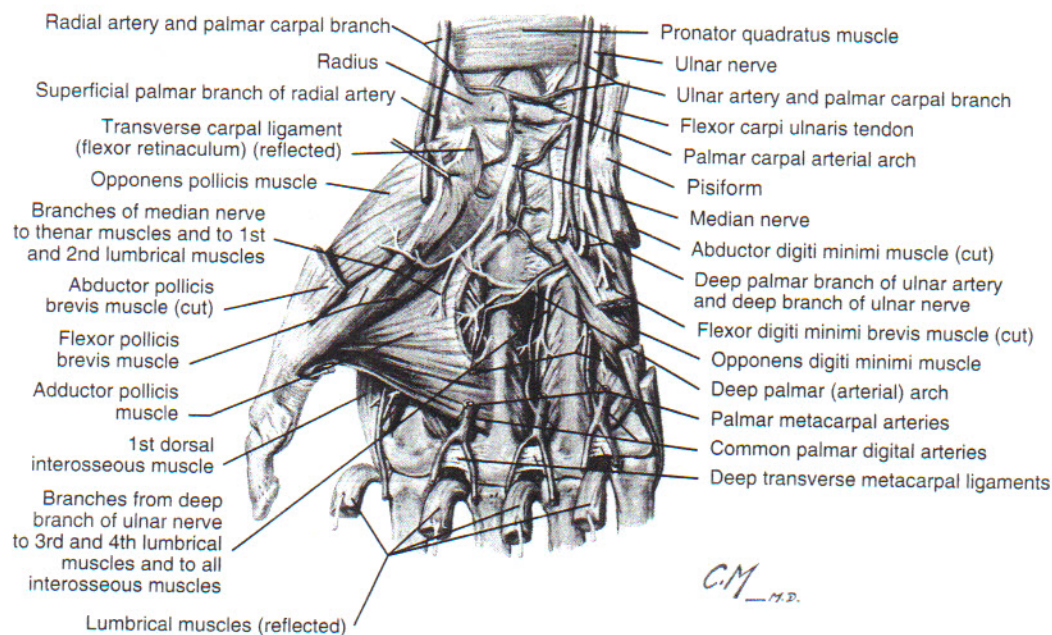


FIG 10-5 Major arterial and nerve supply to the hand. Note the median nerve crossing under the carpal tunnel and the separate structure of the Guyon canal. (Reprinted from Netter Anatomy Illustration Collection, © Elsevier, Inc.)

interscalene triangle: an anatomic space defined anteriorly by the anterior scalene, posteriorly by the middle scalene, and inferiorly by the first rib. This space facilitates the exit of the subclavian vein and brachial plexus in thoracic outlet syndrome.

lateral cutaneous nerve (of forearm): sometimes provides sensation to the lateral side of the thumb metacarpal area.

Martin-Gruber connection: a connection between the median and ulnar nerve in the forearm in which fibers that normally travel with the ulnar nerve from the brachial plexus distally, travel with median nerve until the midforearm and only enter the median nerve at that connection; **Martin-Gruber anastomosis.**

median nerve: the nerve that conducts sensations from the hand to the central nervous system and crosses under the small volar carpal ligament. Supplies some of the small muscles of the thumb including the opponens, the superficial head of the flexor pollicis brevis

(FPB), and the abductor pollicis brevis (APB) but not the adductor and the deep head of the flexor pollicis brevis (FPB); provides sensation for most of the palm and volar thumb, long and index fingers, and thumb side of the ring finger. The motor branch controls muscles surrounding the thumb.

Meissner's corpuscles: pressure receptors at nerve endings in the skin.

proper volar digital nerve and artery: the nerves and arteries after they have divided in the palm and travel along the two volar sides of the finger.

radial artery: major artery on the thumb side of the palm and wrist.

radial nerve, superficial branch: this nerve supplies sensation only; sensory distribution is over the dorsum of the thumb, index finger, long finger, and radial side of the ring finger.

Riche-Cannieu connection: the deep motor branch of the ulnar nerve may send a branch to join the

motor branch of the median nerve. The relevance is that in injuries to the median nerve at the wrist, one may still retain motor function at the wrist.

superficial and deep palmar arterial arch: the superficial and deep connecting arcades of the radial and ulnar artery in the palm.

ulnar artery: artery on the little finger side of the palm and wrist.

ulnar nerve: the nerve crossing the wrist through the Guyon canal and supplying the adductor pollicis, deep head of the flexor pollicis brevis, and all small muscles of the hand, except the thumb and first two lumbricals. The sensation supplied is to the little finger and the little finger side of the ring finger.

Vater-Pacini corpuscle: pain pinpoint receptor.

vinculae: blood vessel bridges to the flexor tendons having a *vinculum brevum* and *vinculum longum*.

Diseases and Structural Anomalies

Most of the diseases that affect the bones and joints of the hand are described in Chapter 2. The specific terminology for deformities caused by rheumatoid arthritis, nerve injuries, and congenital defects related to the hand is listed here. The terminology for diseases of the hand comprises many words not specific to other parts of the anatomy and is divided as follows.

Arthritic Deformities

arthritis (degenerative): commonly seen in the following joints: distal interphalangeal (DIP) (Heberden nodes), proximal interphalangeal (PIP; Bouchard nodes), metacarpophalangeal (MCP; posttraumatic or infection), carpometacarpal (CMC) digits (associated with CMC bossing), trapeziometacarpal (thumb), intercarpal (triscaphe, radiolunate, triquetrohamate, lunatotriquetral), radioscaphoid (seen in postsaphoid nonunions or with scapholunate advanced collapse [SLAC] wrist).

scapholunate advanced collapse (SLAC): after untreated scaphoid nonunion or untreated scapholunate dissociation, there is rotatory subluxation of the scaphoid. Typically will have

radioscaphoid arthritis, sparing the radiolunate joint with proximal migration of the capitate.

arthritis (inflammatory): rheumatoid hand deformities that include the following: flexor or extensor tenosynovitis, tendon ruptures, caput ulnar syndrome (Vaughn-Jackson syndrome), intercarpal collapse or volar carpal subluxation, metaphalangeal volar collapse with ulnar deviation, thumb digits, boutonnière deformity, swan-neck deformity, carpal tunnel syndrome, and intrinsic contractures.

arthritis mutilans: a form of rheumatoid arthritis manifesting extreme loss of bone stock; medullary, cancellous bones and markedly same with cortices.

attenuation (attrition) of tendons: erosion and eventual rupture of tendons by diseased synovium or bony spurs.

crystalline arthropathy (gout): with chronic hyperuricemia, there is recurrent joint inflammation, typically with fever and leukocytosis that affects fingers, wrists, and elbows; medical and surgical treatment indicated.

pseudogout: the deposition of calcium pyrophosphate crystals with episodic inflammation of wrist and metaphalangeal (MP) joints; chondrocalcinosis.

Grind test: a diagnostic test to clinically determine the presence of basal joint arthritis of the thumb by exerting axial pressure on the thumb metacarpal to the trapezium.

progressive systemic sclerosis (PSS): typically scleroderma, Raynaud's subcutaneous calcinosis, resorption of the distal tufts. Diffuse hand involvement with skin thickening and fibrosis.

psoriatic arthritis (PA): typically of the distal interphalangeal (DIP), but any joint can be affected. Joint pain and stiffness can have similar clinical picture to rheumatoid arthritis.

pyogenic arthritis: bacterial infection of a joint.

systemic lupus erythematosus (SLE): deformity similar to rheumatoid arthritis with pain and swelling in the midproximal interphalangeal (PIP) joints and the wrists. Usually systemic, there is relative sparing of articular cartilage until late.

Arthritic Deformities

boutonnière: deformity of the middle finger consisting of a flexion contracture of the proximal interphalangeal joint without a dislocation of the distal interphalangeal joint.

diabetic cheilostoma: a condition with diabetes mellitus characterized by a thickening of the lips and a narrowing of the mouth.

mallet finger: a deformity of the distal interphalangeal joint caused by a traumatic injury to the extensor digitorum tendon.

opera-glass: a deformity of the distal interphalangeal joint caused by a traumatic injury to the extensor digitorum tendon.

radial drift: a deformity of the distal interphalangeal joint caused by a traumatic injury to the extensor digitorum tendon.

swan-neck: a deformity of the distal interphalangeal joint caused by a traumatic injury to the extensor digitorum tendon.

trapeziometacarpal joint: the joint between the trapezium and the first metacarpal.

Type I: a classification of the trapeziometacarpal joint.

Type II: a classification of the trapeziometacarpal joint.

Type III: a classification of the trapeziometacarpal joint.

Type IV: a classification of the trapeziometacarpal joint.

tophus: a collection of inflammatory cells and debris in a joint.

trapeziometacarpal joint: the joint between the trapezium and the first metacarpal.

trapeziometacarpal joint: the joint between the trapezium and the first metacarpal.

trapeziometacarpal joint: the joint between the trapezium and the first metacarpal.

Arthritic Deformities (Specific)

boutonnière deformity: a fixed deformity of the finger consisting of flexion of the proximal interphalangeal joint and extension of the distal interphalangeal joint. A result of rheumatoid destruction of the extensor tendon mechanism at the proximal interphalangeal joint and also secondary to trauma without arthritis. Can be moderate to severe and indicates that a separate classification system exists.

diabetic cheiarthropathy: hand arthritis associated with diabetes; characterized by flexion contracture of the metacarpophalangeal and proximal interphalangeal joints of the fingers, with thickening, induration, and a waxy appearance of the skin.

mallet finger: drop of the distal phalanx due to traumatic or arthritic avulsion to the extensor tendon over the distal interphalangeal (DIP) joint, drop finger.

opera-glass hand: a rare, very advanced stage of arthritis in which the joints are destroyed and the bones become thin, fragile, and shortened.

radial drift: the position toward which the metacarpals tend to drift in rheumatoid arthritis—the alignment of the hand deviates toward the thumb; may apply to the thumb but usually specified.

swan-neck deformity: a static or dynamic position of the finger that exhibits distal interphalangeal (DIP) flexion and proximal interphalangeal (PIP) hyperextension. Seen in posttraumatic or rheumatoid patients. Anatomically, there is failure of the distal extensor mechanism, tightness of the central slip, and proximal interphalangeal (PIP) volar plate laxity. In rheumatoid arthritis, the classification system is as follows:

Type I: PIP joint flexible in all positions of MP joint.

Type II: PIP joint is limited in certain positions.

Type III: PIP joint is limited in all positions.

Type IV: stiff PIP with gross articular destruction.

tophus: accumulation of any crystalline material in the soft tissue; seen commonly in gout.

trapeziometacarpal arthritis: an arthritis at the base of the thumb; often occurs in the absence of systemic disease or previous trauma. Most common in women.

ulnar drift: the position of the fingers in rheumatoid arthritis; the fingers point away from the thumb and are often associated with radial drift at the wrist.

Neuropathies

allodynia: a perception of nonpainful stimulus as painful. This is a symptom of complex regional pain syndrome.

Bouvier's maneuver: application of dorsal pressure over the proximal phalanx to passively flex the metacarpophalangeal joint resulting to straightening of the distal joint and temporary correction of a claw deformity in ulnar nerve palsy.

complex regional pain syndrome (formerly reflex sympathetic dystrophy): syndrome of abnormally intense, inappropriately prolonged pain, not a reflection of actual or impending tissue damage commonly seen after trauma, in a variety of neurogenic and vascular sequelae.

compressive neuropathy: loss of motor or sensory nerve function, acute or chronic, due to extrinsic compression. Entrapment can occur within tight fibroosseous tunnels or as a result of tumor, hemorrhage, or metabolic changes, causing swelling of soft tissues around the nerve.

dysesthesia: an unpleasant spontaneous sensation occurring in patients with chronic regional pain syndrome.

Halstead maneuver: a compression test of the thoracic outlet by moving the shoulders downward and backward with the chest protruding to draw the clavicle closer to the first rib, thus narrowing the thoracic outlet.

Horner's syndrome: strongly correlated with avulsion of the C8 and T1 nerve root in brachial plexus injury. This includes ptosis, miosis, and anhidrosis.

hyperesthesia: increased sensitivity to a stimulus that would normally not be painful; seen commonly in chronic regional pain syndrome.

hyperpathia: a state of exaggerated and very painful response to stimulation seen in complex regional pain syndrome.

Jeanne's sign: hyperextension of the metacarpophalangeal joint of the thumb doing key pinch or gross

grip due to paralysis of the adductor pollicis muscle, which acts as a first metacarpal adductor seen commonly in ulnar nerve palsy.

Klumpke's palsy: a paralysis due to isolated injury to the C8 and T1 nerve roots either in birth plexus injuries or traumatic injuries later in life.

phantom limb pain: a sensation after amputation of a limb. The patient may still have sensation that the amputated part is still present. This may be painful and may be due to representation of the limb in the terminal neuromatous stumps in the amputated part.

Pitres Testut sign: an inability to actively move the long finger in radial and ulnar deviation with palm placed flat on the table. Demonstrating paralysis of the second and third dorsal interosseous muscles in ulnar nerve palsy.

Pollock's sign: loss of extrinsic power with inability to flex the distal joint of the ring and little fingers due to the weakness of the flexor digitorum profundus through the fourth and fifth fingers in ulnar nerve palsy.

post-tourniquet syndrome: characterized by edema, stiffness, pallor and weakness without paralysis, and subjective numbness without objective anesthesia due to prolonged use of tourniquet in upper extremity surgery.

reflex sympathetic dystrophy (RSD): usually post-traumatic (major or minor) pain dysfunction syndrome. Thought to be due to abnormal modulation of afferent pain signals with possible short-circuiting of somatic and autonomic nerve fibers. Attendant autonomic nervous system hyperactivity will produce abnormal peripheral small vessel response to cold and heat stimulus. Symptoms include hyperpathia (increased pain at rest), allodynia (painful response to a nonpainful stimulus), erythema (brawny edema), joint stiffness, and loss of skin elasticity. Osteoporosis and complete loss of dexterity result. Bone scan and tomography are diagnostic, and treatment includes physical therapy, oral medications, and a sympathetic ganglion blockade; also called **autonomic dystrophy**, **shoulder-hand syndrome**, **Sudeck atrophy**, **causalgia**, and **sympathetic maintained pain syndrome (SMPS)**.

Roo's classification: classification of thoracic outlet syndrome depending on the segment of the brachial plexus involved, either upper, lower, or combined compressions.

Roo's test: a clinical test to diagnose thoracic outlet syndrome where the patient abducts both arms 90 degrees and flexes with 90 degrees of elbow flexion, repeatedly opening and closing the hands to elicit numbness, tingling, or weakness in both hands.

Semmes-Weinstein monofilament tests: an array of monofilaments placed perpendicular to wooden or plastic rods that are held against the skin in progressive thickness and progressive skin resistance used to test innervation and density at the fingertips in nerve injury areas.

Spurling test: a clinical test for cervical nerve root compression by compressing the nerve root at the foraminal exit in the cervical spine. Compression is applied to the patient's head. A positive test represents a spray of numbness and pain shooting down the ipsilateral arm.

Sunderland classification (grades of nerve injury):

I neuropraxia: local conduction block, nerve in continuity, no wallerian degeneration, all nerve elements intact. No Tinel's sign.

II axonotmesis: axonal damage; wallerian degeneration distally; endoneurium, perineurium, and epineurium intact; nerve sprouting; progress excellent.

III axonotmesis: axon and endothelium are disrupted, perineurium intact. Nerve mismatching with regeneration. Recovery is dependent on degree of neural matching, unpredictable; advancing Tinel's sign and wallerian degeneration distally.

IV axonotmesis: axon, endoneurium, and perineurium violated. Nerve is grossly in continuity held by epineurium, advancing Tinel's sign, regenerative units trapped in scar; requires surgical intervention and traction (3-month wait before traction).

V neurotmesis: complete nerve transection requiring surgical intervention by repair graft or conduit.

VI neuroma in continuity: nerve grossly in continuity, but injured area is encased in nerve

scar with each fascicle fascicles w repair thes

traction injury: overpull that ing in neuro seen in brachi pull the ner resulting in p

Median Neurop
anterior inter

elbow and fo the flexor dig pollicis longi (PQ). Electro tive therapy r failing that, si indicated.

carpal tunnel sy

pression at tl surrounding finger motion elevation occ crease. Then: untreated. Pat dysesthesia in tion. Conserv cases, and, fail carpal tunnel i and nerve con

pronator syndr

in the elbow pain, with nu the median r are occasiona tried for sever pression of th

Radial Neuropa
posterior intrac

sion of the mc arcade of Fro and wrist exter

scar with varying degrees of nerve injury in each fascicle. The challenge is to identify the fascicles with a higher grade of injury and to repair these.

traction injury: refers to injury to nerve tissue from an overpull that exceeds 10% of resting length resulting in neuronal dysfunction, which is commonly seen in brachial plexus injuries. This injury may also pull the nerve root out of the cervical spine resulting in pseudoceles.

Median Neuropathy

anterior interosseous nerve syndrome: anterior elbow and forearm pain and motor weakness of the flexor digitorum profundus (FDP) II, flexor pollicis longus (FPL), and pronator quadratus (PQ). Electromyography may be helpful. Conservative therapy may be tried for several months, and, failing that, surgical decompression of the nerve is indicated.

carpal tunnel syndrome (CTS): a median nerve compression at the wrist caused by chronic synovitis surrounding the flexor tendons with repetitive finger motion or squeezing. Maximum pressure elevation occurs 3 to 4 cm distal to the volar wrist crease. Thenar motor loss may be included if untreated. Patient describes numbness, tingling, and dysesthesia in the hand at the median nerve distribution. Conservative therapy is indicated in chronic cases, and, failing that, surgical decompression of the carpal tunnel is necessary. Electromyograms (EMGs) and nerve conduction studies are usually diagnostic.

pronator syndrome: entrapment of the median nerve in the elbow causes anterior elbow and forearm pain, with numbness, tingling, and paresthesias in the median nerve distribution. Electrodiagnostics are occasionally helpful. Conventional therapy is tried for several months, and, failing that, decompression of the median nerve is indicated.

Radial Neuropathy

posterior intraosseous nerve syndrome: compression of the motor branch of the radial nerve near the **arcade of Froese** that causes weakness of the finger and wrist extensors. Electrodiagnosis and conservative

treatment are not helpful. Surgical release of the radial nerve may improve function, but tendon transfers may be necessary.

radial sensory nerve entrapment (Wartenberg syndrome): the radial sensory nerve can become entrapped in the distal third of the forearm as it emerges between the brachioradialis and the extensor carpi radialis longus (ECRL). Patient experiences numbness and dysesthesia in the dorsoradial hand and wrist, provoked by hyperpronation of the forearm. Sensory nerve conduction studies are helpful, and surgical release is curative in most cases; **brachialgia statica paresthetica**.

radial tunnel syndrome: usually misdiagnosed as **resistant tennis elbow**, it is posterolateral elbow pain accentuated on resisted supination of the forearm or extension of the middle finger. Electromyography and nerve conduction studies are helpful. Treatment includes rest, splinting, and avoiding stressful activities.

wrist drop: a radial nerve palsy with loss of muscle control for wrist extension. This can be due to a variety of central and peripheral nerve conditions but is most commonly associated with radial nerve palsy; **posterior intraosseous nerve syndrome**.

Ulnar Neuropathy

cubital tunnel syndrome: entrapment of the ulnar nerve at the elbow due to fibrous tissue in the fibroosseous arcade and the two heads of the flexor carpi ulnaris (FCU) as a result of prolonged elbow flexion. Early on, symptoms are sensory and involve the fourth and fifth digits; later, intrinsic motor weakness predominates. Surgical compression and/or ulnar nerve transposition is necessary.

Charcot-Marie-Tooth disease: in the hand, spontaneous deterioration of the neuromuscular complex will affect the ulnar nerve and cause severe intrinsic wasting with a characteristic clawhand deformity; **intrinsic minus deformity**.

double (multiple) crush syndrome: compression of a peripheral nerve (i.e., median or ulnar nerve) in two or more locations. There is cervical root compression at C-6 or C-7 and carpal tunnel syndrome. Three types exist: multiple anatomic regions along

a peripheral nerve, multiple anatomic structure access to peripheral nerve with anatomic region superimposed on a neuropathy, or a combination of the above. These complex conditions require a multifactorial approach. Prognosis is guarded.

focal dystonia: a condition whereby muscles become imbalanced when some muscles are used more than others. This is due to repetitive motions of the hand, such as seen in musicians (pianists or string or brass instrumentalists). The brain does not send proper signals to the affected muscles, resulting in spasms and seizures of the hand. Sometimes the arm is affected. Treatment is in the form of electrical stimulation, ultrasound, exercise, or surgery.

intrinsic minus hand: in low ulnar nerve palsy, will cause intrinsic palsy with a characteristic metacarpophalangeal (MCP) hyperextension and proximal interphalangeal (PIP) and distal interphalangeal (DIP) sensory deformity. Results from any interruption of intrinsic function; intrinsic minus deformity, intrinsic plus deformity; **clawhand deformity**.

intrinsic plus hand: loss of extrinsic muscle function or intrinsic contracture will cause metaphalangeal flexion and interphalangeal extension.

monkey paw: an adduction and extension of the thumb in which it cannot be opposed. It is unable to touch the tips of the fingers due to weakness of the opposing muscles of the thumb, as in a lesion of the median nerve.

peripheral neuropathy: intrinsic axonal or myelin pathologic condition usually due to an underlying metabolic malfunction or toxic state (i.e., diabetes, renal failure, alcoholic neuropathy).

Saturday night palsy: localized pressure palsy (e.g., in an alcoholic who falls asleep on a rested arm on a hard object); a first-degree neuropraxia occurs, which is worsened by an underlying alcoholic neuropathy.

tardy ulnar palsy: delayed chronic ulnar neuropathy secondary to chronic stretching of the nerve in the cubital tunnel due to cubitus valgus deformity at the elbow.

thoracic outlet syndrome: a constellation of signs and symptoms with multifactorial etiology. Common complaints include aching pain and heaviness in the neck, shoulder, and upper arm with numbness

and tingling mainly to the fourth and fifth fingers. Symptoms worsen with arm elevation to include chest pain, tightness, and headaches. Thoracic outlet syndrome is believed due to compression of the brachial plexus over the cervical rib and between the scalenus anterior and scalenus medius muscles; in early adult life with shoulder sagging, brachial plexus traction can result. Initial treatment must include physiotherapy. Surgery may be indicated if symptoms persist for more than 1 year. Related conditions are *brachial plexus compression*, *scalenus anterior syndrome*, and *hyperabductor syndrome*.

ulnar tunnel syndrome: entrapment of the ulnar nerve at the wrist (Guyon canal). Could be acute or caused by repetitive trauma. Electrodiagnostics studies are helpful. Surgical release may be necessary.

vibration white finger syndrome: digital arterial or nerve injury in the hand from using tools with at least 2000 to 3000 cpm; characterized by Raynaud's phenomenon: cold intolerance, numbness, tingling, and weakness with loss of dexterity.

Congenital Anomalies

Classification of Upper Limb Anomalies

The International Federation of Societies for Surgery of the Hand (IFSSH) has adopted a classification system for upper limb anomalies that affect hand function. An example is given for each group.

I. Failure of formation of parts.

Transverse congenital amputations, constriction band syndrome (amniotic Streeter bands).

Longitudinal (radial, ulnar) hemimelias, phocomelias, hypoplastic digits.

II. Failure of differentiation of parts (incomplete morphogenesis).

Shoulder: Sprengel deformity.

Arm and forearm synostosis: humeroradial, humeroulnar, radioulnar.

Hand synostosis: syndactyly, camptodactyly, congenital trigger digit, clinodactyly.

III. Duplication.

Polydactyly triphalangism, central polydactyly (polysyndactyly, mirror hand).

IV. Overgrowth

Macroduct limb h

V. Undergrowth

Brachydact

VI. Constriction

(bands)

VII. Generalized

Dwarfism

malies

syndr

Agenesis

acheiria: absence

acquired thumb

flexion

after birth

can be relieved

volar base

or snaps.

thumb is

acrosyndactyly

dactylized

connected

(skin) or (

tures). The

adactyly: absence

amelia: total

amputation

amniotic band

that may be

or anywhere

conjunctive

foot or c

depends on

plete if the

are evident

associated

rings asso

and (4) in

tion of ne

are initiate

Streeter b

Apert syndrome

phalanx, 1

and othe

- IV. Overgrowth (gigantism).
Macrodactyly, lipofibromas, hamartoma of nerve, limb hypertrophy, hemihypertrophy.
- V. Undergrowth.
Brachydactyly.
- VI. Constriction ring syndrome (amniotic Streeter bands).
- VII. Generalized skeletal anomalies.
Dwarfism, arthrogryposis, chromosomal anomalies (i.e., Madelung deformity); **Klippel-Feil syndrome**.

Agensis

acheiria: absence of the hand.

acquired thumb flexion contracture: in children, a thumb flexion contracture that usually develops *after* birth, and, if present for more than a year, can be relieved by release of the A1 pulley at the volar base of the thumb. The thumb rarely catches or snaps. Hence, the term **congenital trigger thumb** is not appropriate for this condition.

acrosyndactyly: terminal interconnection of the syndactylized digits. These may or may not be connected proximally. The connection may be simple (skin) or complex (bone or other associated structures). These are commonly seen in Apert syndrome.

adactyly: absence of the digits.

amelia: total absence of the upper limb (congenital amputation).

amniotic bands: congenital circumferential crease rings that may be present at a fingertip or at upper arm level, or anywhere in between. This can be isolated or in conjunction with associated anomalies such as clubfoot or cleft palate. Neurovascular embarrassment depends on the depth of the crease and may be complete if the crease goes down to the bone. Four types are evident: (1) simple constriction rings; (2) rings associated with distal lymphedema or deformity; (3) rings associated with soft tissue fusion of distal parts; and (4) intrauterine amputations. If there is any question of neurovascular compromise, Z-plasty releases are initiated in at least two stages; **constriction bands**, **Streeter bands**, **Streeter dysplasia**.

Apert syndrome: hand anomalies that include delta phalanx, metacarpal synostosis, complex syndactyly, and other anomalies including skull and facial.

Digits are usually short, deformed, stiff, and at the tips "spoon hand."

aphalangia: absence of phalanges.

arachnodactyly: long spider-like fingers seen commonly in Marfan's syndrome.

arthrofibrosis: joint capsular thickening and scarring with resistant stiffness seen in either posttraumatic situations, chronic spasticity, or an arthrogryposis.

arthrogryposis (arthrogryposis multiplex congenita): joint contractures present at birth; cause is not yet known. Muscle weakness with immobility leads to contractures. Absent skin lines give it a waxy appearance. There are three groups:

single localized deformity (in upper extremity): forearm pronation contracture, palm clutched thumb, selected loss of wrist and finger extensors, and intrinsic muscle contracture.

whole upper extremity involvement: no shoulder girdle musculature; thin, tubular arms and forearms; straight, stiff elbows; flexion and ulnar deviation of the wrist; and stiff fingers and adducted thumbs.

global rigidity with associated deformities: polydactyly or windblown deformity (intrinsic plus hand).

Bayne's classification: a range of radial longitudinal congenital deficiencies describing the spectrum of deficits on the radial side of the forearm from hypoplastic thumb to complete absence of all radial structures including the radial bone.

Beal's syndrome: a system to categorize the different types of camptodactyly and congenital contractures in fingers.

Bell's classification: spectrum of inherited anomalies that include brachydactyly as the dominant feature.

bifid thumb: a generic term for thumb duplication or preaxial polydactyly. Wassel classification is the most commonly used.

I: bifid distal phalanx (IP joint common).

II: duplicate distal phalanx (first proximal phalanx).

III: bifid proximal phalanx (MP joint common).

IV: duplicate proximal phalanx (first metacarpal most common).

V: bifid metacarpal (CMC joint common).

VI: duplicate metacarpal.

VII: triphalangeal thumb.

brachydactyly ("short fingers"): digital hypoplasia may result from an arrest of development and it may affect any or all component tissues in a digit. It can be isolated or in conjunction with other congenital anomalies.

camptodactyly ("bent finger"): congenital nontraumatic flexion contracture in the sagittal plane of the proximal interphalangeal joint of the little finger, usually accompanied by metacarpophalangeal joint hyperextension. This is usually associated with other anomalies; causes are multifactorial, treatment is difficult, and outcome is uncertain.

carpal coalition: a congenital fusion or synostosis between two carpal bones, most commonly lunate and triquetrum or capitolunate. These are usually asymptomatic.

clashed thumb: refers to a spectrum of congenital thumb abnormalities resulting from deficiency of the thumb extensor mechanism. Overactivity of thumb extrinsic and intrinsic flexors.

cleft hand: a central ray deficiency (ectrodactyly, oligodactyly) secondary to failure of formation of parts. High association with extraskelatal (i.e., cardiac) defects that may be metacarpal and carpal anomalies or deficiencies. These present deep clefts that may extend down to the carpus. Despite the cosmetic appearance, function may be surprisingly good; **lobster-claw hand** (archaic).

clinodactyly ("bent finger"): radial or ulnar deviation of the digit tip in coronal plane. Usually this is expressed as radial deviation of the little finger at the distal interphalangeal joint and is associated with other anomalies.

congenital trigger thumb: a congenital locking or clicking of the thumb with flexion posture of the interphalangeal joint. Nodular formation on the flexor pollicis longus tendon or tendon sheath thickening is common. Tendon sheath release is curative.

congenital ulnar drift: ulnar deviation of the digits at the metacarpophalangeal (MCP) joint with proximal interphalangeal (PIP) joint flexion deformity. Thumb webbing is also present. General muscular hypoplasia in the arm is present. Associated with craniofacial deformities and a markedly narrowed mouth; also called **windblown hand**, **whistling face syndrome**, **Freeman-Sheldon syndrome**.

delta phalanx: a triangular-shaped bone interposed in the digit between two normal phalanges. A C-shaped physis is common and will cause a sharp angular digital deformity.

Ellis-Van Creveld syndrome: a form of ulnar polydactyly that is postaxial (multiple digits coming out of the ulnar aspect of the hand).

Fanconi anemia: pancytopenia, hematophoretic anomalies associated with radial hemimelia (autosomal recessive).

flipper hand (phocomelia): congenital absence of the arms; the hands appear to arise directly from the shoulder.

floating thumb (pouce floutant): an unstable hypoplastic thumb that may be connected to the hand by skin and a simple neurovascular pedicle. These digits are generally useless and are best removed.

Freeman-Sheldon syndrome: a condition affecting the hands and feet with a characteristic appearance of arthrogryposis as a dominant feature.

hemimelia: absence of the forearm and hand.

heart-hand syndrome (Holt-Oram syndrome): cardiac septal defects, autosomal dominant and seen with radial ray deficiency.

hereditary multiple exostosis: autosomal dominant inheritable disease characterized by multiple osteochondromas growing from the physis of long bone, pelvis, rib, scapula, and vertebra. This commonly appears in forearm bones and short tubular bones of the hand.

hyperphalangism: an extra (fourth) phalanx interposed between the phalanges of a finger. There are no extra digits. The digits are usually short.

hypoplastic thumb: an incompletely developed thumb that can range from a short thumb to complete absence. This is usually seen in conjunction with many associated abnormalities. There are five types: short thumb, adducted thumb, abducted thumb, floating thumb, and absent thumb.

Kirner deformity: parrot-beak convexity of the nail bed due to volar bending of the distal phalanx. This may not be obvious until age 12.

macrodactyly: a disproportionately large digit apparent at birth or early childhood. In a "true" case, all structural components may be enlarged including vessels and nerves. Commonly, there is a

marked tissue.

Madelung disorder
radius. The bowing of the deformity age.

Marfan's syndrome
that causes (with congenital joint

mirror hand
two ulna presents genetic disorder in

monodactyly
seen as polydactyly

Poland syndrome
associated

polydactyly
usually for the hand

polysyndactyly
the index complex

radial clubfoot
radial structure

There are (2) hypoplastic radius; (1) be associated anomalies

be isolated skeletal defects; fistula; Holt-Oram syndrome

talipes equinovarus
affecting forearm bones, nerves, with other

marked increase in subcutaneous fiber or fatty tissue.

Madelung deformity: congenital growth plate disorder of the volar ulnar physis of the distal radius. This will cause a severe volar and ulnar bowing of the radius, initially normal at birth, and the deformity becomes evident by 8 to 12 years of age.

Marfan's syndrome: a disease of connective tissue that causes arachnodactyly (long, pencil-like fingers) without flexion contractures. Patients with this condition also have loose ligaments in their finger joints.

mirror hand (ulnar dimelia): the forearm contains two ulnas and has no radius. Typically, the patient presents with eight digits. This is a rare spontaneous genetic mutation that, when present, can be passed down in an autosomal dominant fashion.

monodactyly: a single-digit hand that may also be seen as part of a spectrum of cleft hand disease.

Poland syndrome: thumb ray or finger deformity associated with absence of pectoral muscle head.

polydactyly: extra digits that may be complete or partially formed. These can be postaxial (ulnar side of the hand) or preaxial (on the thumb).

polysyndactyly (central polydactyly): polydactyly of the index and ring fingers, usually associated with complex syndactyly. These are usually bilateral.

radial clubbed hand: total or partial absence of radial structures of the hand and forearm (preaxial). There are four types: (1) short distal radius; (2) hypoplastic radius; (3) partial absence of the radius; (4) total absence of the radius. These may be accompanied by thumb, index, or long finger anomalies. Muscle or neurovascular anomalies can be isolated as part of a syndrome complex (i.e., vertebral defects, imperforate anus, tracheoesophageal fistula, and radial and renal dysplasia [VATER], Holt-Oram syndrome). Hand is radially deviated; **talipomanus**.

radial deficiency: a series of congenital malformation affecting the radial aspect of the hand, wrist, and forearm with varying degrees of hypoplasia of the bones, joints, muscles and tendons, ligaments, nerves, and blood vessel. This may be associated with other systemic conditions.

radio-ulnar synostosis: a congenital or posttraumatic fusion of the radius and ulna seen generally near the proximal radial ulnar joint of the elbow, but it can occur distally as well.

supernumerary digits: extra nubbins of fingers and thumb with no function.

sybrachydactyly: literally shortened, stiff digits. Seen commonly in the spectrum of cleft hand disease.

sympalangism: hereditary dysplasia and ankylosis of digital joints, most notably the proximal interphalangeal (PIP) joint. There may be partial or total bone bridging.

syndactyly: a congenital joining of two or more digits; the connection may be complete or incomplete, simple or complex. Simple-shared element of skin and subcutaneous tissue. Complex shared element of skin, subcutaneous tissue, tendon, bone, and neurovascular structures.

synostosis: fusion between two adjacent parallel bones (i.e., metacarpals or radius and ulna). Term may also be used for humeral-radial fusion.

sympolydactyly: a congenital anomaly resulting in the formation of extra phalanges or digits within an conjoined digital nerve with syndactyly of skin and bony structures.

TAR syndrome: thrombocytopenia, absent radius; complete absence of the radius may be present (autosomal recessive).

trident hand: typical hand appearance of an achondroplastic dwarf where there is a persistent space between the ring and long fingers.

triphalangeal thumb: interposition of an extra phalanx between two normal phalanges of the thumb; can at times be functionally normal or cause marked deformity or malfunction. The extra phalanx can be normal or be a delta phalanx. Often seen with congenital heart disease.

triplicate thumb: a variant form of preaxial polydactyly involving three thumbs; all are markedly diminished in size and may lack one or more tissue elements.

ulnar (postaxial) deficiency: usually isolated with severe limitation of elbow function; hypoplasia of ulna, partial aplasia of the ulna (absence of distal or middle third of the ulna), total aplasia of the ulna; **radiohumeral synostosis**.

ulnar variance: relative position of the distal ulnar joint referred to the level of the ulnar side of the distal radial joint, as determined on an anteroposterior radiograph that is obtained with neutral pronation and supination. A longer ulna is called a **positive variance**, and a shorter ulna is called a **negative variance**, measured in millimeters.

VATER syndrome: vertebral anomalies, anal atresia, tracheoesophageal fistula, renal and vascular anomalies, accompanied by a radial clubhand.

whistling face syndrome: an autosomal dominant condition affecting the hands and feet with a characteristic facial appearance in the form of arthrogryposis, which is a congenital and pathologic stiffness of the arms or legs down to the hands or feet in characteristic postures.

Muscle and Tendon Disorders

trigger finger (acquired): entrapment of finger flexor tendons usually under the proximal A1 pulleys; usually due to a disproportion between the flexor tendon and the flexor tendon sheath. Usually, the cause is obscure, with thickening of the pulley tissues and/or nodular formation about the tendon. This can be secondary (i.e., due to diabetes, rheumatoid arthritis, or gout). Conservative measures and steroid injections may help, but surgery is usually curative.

boutonnière deformity (posttraumatic): usually due to a central slip rupture of the middle phalanx with an injury to the triangular ligaments. Volar subluxation of the lateral bands below the flexion axis of the proximal interphalangeal (PIP) joint will cause a fixed flexion attitude of the PIP joint.

carpal pedal spasm: an intrinsic plus position with wrist flexion usually seen in hypercalcemia.

de Quervain's disease: stenosing tenosynovitis of the first dorsal extensor compartment, usually involving the extensor pollicis brevis (EPB) and abductor pollicis longus (APL).

intersection syndrome: pain and swelling over the place where the muscles of the first dorsal extensor compartment cross over the muscles of the second compartment. This is believed to be a tenosynovitis of the second dorsal compartment.

Landsmeer test: a test that elicits a tight oblique retinacular ligament of Landsmeer as seen in boutonnière's deformity where passively extending the proximal interphalangeal joint sends the interphalangeal joint into a tight fixed extension posture. Also, the particular anatomy of Landsmeer's ligament is volar to the proximal interphalangeal joint and dorsal to the distal interphalangeal joint.

lumbrical plus finger deformity: a condition in which there is overactivity of the lumbricals creating a paradoxical extension of the proximal and distal interphalangeal joints with attempted flexion of the fingers.

peritendonitis stenosans/digitus saltans: an archaic term used to describe conditions of stenosing tenosynovitis such as those found in de Quervain's disease, flexor carpi radialis tendonitis, and trigger digits.

quadregia: in a setting in which the profundus tendon to a digit is contracted or repaired too tightly, there will be a limitation of proximal excursion of the remaining flexor digitorum profundus (FDP), causing a weak grip (as all the FDP tendons usually share a common muscle belly).

tendovaginitis: form of tendon entrapment seen in trigger digits and de Quervain's tenosynovitis by tight retinaculum or tenosynovitis obliterating the space between the tendons and the overlying retinaculum.

tetraplegia: neurologic injury secondary to cervical spine trauma. Altered functional capacity of the hand, depending on the level of injury. This will also dictate operative and nonoperative intervention. A system has been devised:

Tetraplegia International Classification

Functional Group	Root Level Intact
Brachioradialis	C-5, C-6
Extensor carpi radialis longus	C-7 (possibly C-8)
Extensor carpi radialis brevis	C-7, C-8
Pronator teres	C-7, C-8
Flexor carpi radialis	C-8
Extensor digitorum communis	C-8
Extensor pollicis longus	T-1
Partial digital flexion	T-1
Lacks intrinsic only	T-1
Miscellaneous (i.e., Brown-Séquard syndrome or syringomyelia)	

Volkman

forearm
ischemic
untreated
in musculature
is ulnar
The flexor
pollicis longus
There is

"no man's
digital flexion
A2 pull
fraught

Vaughn-Ja
the finger
radial ulnar

washer wrist
Quervain's
tendons

Vascular acrocyanosis

exposure
cold. The

Buerger's
inflammation
in men.
progress
of the wrist

hypothymia
aneurysm
of the
hamate
localized
common

Kienböck
mediated

subsequent
netic res
fine-tune

Lichtman
follows:

Stage I
bone

Stage II
subcl

Volkmann contracture: contracture affecting the volar forearm musculature as a result of scarring after an ischemic insult. This is the usual sequela of an untreated volar muscle compartment syndrome (seen in muscle crush injuries or forearm fracture). Circulation is usually impaired in the center of the forearm. The flexor digitorum profundus (FDP) and flexor pollicis longus (FPL) muscles are most severely affected. There is a mild, moderate, classic, or severe type.

"no man's land": usually refers to an injury to the digital flexor tendons at zone II (under the A1 and A2 pulleys). Until recently, injury to this area was fraught with technical difficulty and poor results.

Vaughn-Jackson syndrome: rupture of ring and little finger extensors due to synovitis at the distal radial ulnar joint.

washer woman's sprain: an archaic description of de Quervain's tenosynovitis, tendonopathies of the tendons of the first dorsal extensor compartment.

Vascular Disorders

acrocyanosis: seen in Raynaud's phenomenon. With exposure to cold, the fingers become deep blue and cold. This is usually due to peripheral vasospasm.

Buerger disease (thromboangiitis obliterans): an inflammatory thrombosis seen in smokers, usually in men. Digital arteries are affected. The disease is progressive, leading to digital loss and possibly loss of the whole hand.

hypothenar hammer syndrome: an ulnar artery aneurysm or thrombosis due to repetitive striking of the hypothenar eminence and the hook of hamate region against a hard blunt object; typically, localized pain, digital pallor, and cold sensibility are common symptoms.

Kienböck disease: a posttraumatic, vascularly mediated avascular necrosis of the lunate with subsequent collapse, dislocation, and arthrosis. Magnetic resonance imaging (MRI) and bone scan have fine-tuned the classification; **isolated dislocation.**

Lichtman classification for Kienböck disease is as follows:

Stage I: normal radiographic findings, positive bone scan, questionable linear fractures.

Stage II: lunate sclerosis without collapse. MRI subclassification:

IIA: T2 focal signal intensity increase.

IIB: T2 focal signal intensity loss.

IIC: T2 generalized signal intensity increase.

IID: T2 generalized signal intensity loss.

Stage III: lunate sclerosis, fragmentation, and collapse.

Stage IV: stage III plus degenerative changes of the carpus.

Traumatic Disorders

annulus fracture: fractures of the hook of the hamate usually caused by compression force as a direct blow.

Barton's fracture: a intra-articular fracture involving either the dorsal or the volar lip of the distal radius resulting in either dorsal or volar subluxation of the lunate.

chauffeur's fracture: displaced fracture of the radial styloid accompanied by ulnar translocation of the carpus.

dye punch fracture: a type of intra-articular distal radius fracture involving the compression of the lunate facet of the distal radius.

factitious edema: history of minor trauma followed by persistent dorsal forearm pain, swelling, and tenderness due to repeated self-inflicted trauma; **secretan edema.**

fragment specific fixation: a method of repairing the distal radius using a small plate to fix small fractures to the main body of the bone.

gamekeeper's thumb: an abduction laxity of the thumb at the metacarpophalangeal joint due to acute or chronic disruption of the ulnar collateral ligament of the finger joint.

Herbert's classification of scaphoid fractures: a four-part classification describing scaphoid fractures, which includes stable acute fractures, unstable acute fractures, delayed union, and established nonunion.

Holstein-Lewis fracture: a fracture of the distal humerus in which the radial nerve is in particular jeopardy. The proximal spike of the spiral fracture breaks through the lateral cortex of the humerus near where the radial nerve is most grossly opposed to the bone.

Hotchkiss fracture: a classification system describing fractures of the radial head and neck in trauma situation.

interdigital contracture: results from extensive scarring about the hand resulting in cicatrix forming in between the digits preventing digital abduction; seen commonly in severe burns of the hand.

Jahss maneuver: a method of closed reduction of metacarpal neck fractures flexing the metacarpophalangeal (MCP) joint and the proximal interphalangeal (PIP) joint and pushing upward on the flexed PIP joint while applying a cast, flexing the MCP joint into maximal flexion. The PIP joint is usually then brought out into extension.

lunotriquetral dissociation: a condition whereby a lunate becomes volar-flexed in sagittal plane due to a dissociation between it and the adjacent triquetrum.

malrotation: a condition whereby there is a mismatch between the proximal and distal ends of a fracture of a tubular bone in which the distal end of the fracture rotates relative to the proximal end on its long axis. This can cause finger overlap.

Melone's classification: a four-part classification of distal radius fractures that identifies specific intra-articular fragments of the distal radius and rank them in order of severity based on displacement.

negative pressure therapy: a technique that uses a suction apparatus on a mangling high-energy wound. This technique removes exudates, decreases edema, closes the dead space, and promotes wound healing commonly seen in the treatment of wartime injuries.

Palmer classification: for triangular fibrocartilage complex (TFCC) injury.

Class 1: traumatic.

Type A: central perforation.

Type B: medial avulsion (ulnar attachment), with or without distal ulnar fracture.

Type C: distal avulsion (carpal attachment).

Type D: lateral avulsion (radial attachment), with or without sigmoid-notch fracture.

Class 2: degenerative (ulnocarpal impaction syndrome).

Stage A: TFCC wear.

Stage B: TFCC wear with lunate and or ulnar chondromalacia.

Stage C: TFCC perforation with lunate and or ulnar chondromalacia.

Stage D: TFCC perforation with lunate and/or ulnar chondromalacia and lunotriquetral ligament perforation.

Stage E: TFCC perforation with lunate and or ulnar chondromalacia and lunotriquetral ligament perforation, and ulnar carpal arthritis.

peritendinous fibrosis: scarring around a tendon.

pseudoclawing: an intrinsic minus position with metacarpophalangeal hyperextension and proximal interphalangeal joint flexion due to flexion malunion of metacarpal neck fractures.

radial styloidectomy: the excision of the radial styloid done usually in conjunction with scaphoid excision and four-poster fusions in the reconstruction of SLAC wrist.

Rolando fractures: comminuted intra-articular fractures of the base of the thumb metacarpal.

scaphoid ring sign: a scapholunate dissociation in which the scaphoid collapses into flexion and has a foreshortened view on the anterior-posterior (AP) x-ray. The distal end of the scaphoid appears to have radial band with a ring superimposed on it.

scaphoid shift test: a test that determines the integrity of the scapholunate ligament by mobilization from pressure supply to the palmar tuberosity of the scaphoid while the wrist is moved from ulnar to radial deviation. A positive test is seen in a patient with scapholunate dissociation. The scaphoid no longer can strain proximally and subluxes out of the scaphoid fossa of the distal radius. When the pressure is released, the scaphoid goes back into position and a typical snapping occurs.

scapholunate ballottement test: with the lunate stabilized with the thumb and index finger and the scaphoid held over the other hand, a dorsal volar alternating pressure between the scaphoid and the lunate elicits pain and crepitance as well as instability of the joint in scapholunate dissociation.

shear testing for lunotriquetral dissociation: a ballottement test for lunotriquetral dissociation secondary to interosseous injury. The lunate and triquetrum are held stably by the thumb and index fingers of both hands shifted dorsally and volarly relative to one another. A positive test elicits crepitance, pain, and increased movement between the lunate and triquetrum.

skier's thumb: ligament thumb s in fall o thumb a

Stener lesion: eral liga joint of and roll the add will usu

turret exostosis: of the n exostosis matic in

ulnar impaction: the ulna onto the in which ing an u

Specific Distal Radius:

Wrist Dislocation: In a distal r reference t nology des ship to the

carpal instability: pal collaj in the pr triquetra

carpal instability: collapse connecti other ext

Desault's: displacer

dorsal interosseous ligament: zag colla the wrist dorsally. scaphoid dissociat follows t

skier's thumb: an acute rupture of the ulnar collateral ligament of the metacarpophalangeal joint of the thumb seen commonly in skiers, but generally seen in fall on outstretched hands, hyperabducting the thumb at the MP joint.

Stener lesion: in a complete tear of the ulnar collateral ligament of the metacarpophalangeal (MCP) joint of the thumb, the ligament may avulse distally and roll up proximally, causing an interposition of the adductor aponeurosis. Nonoperative treatment will usually result in a chronically unstable thumb.

turret exostosis: a painful mass on the dorsal aspect of the middle phalanx seen on lateral x-ray as an exostosis (**bone spur**). This is believed to be traumatic in origin.

ulnar impaction syndrome: excessive pressure from the ulnar aspect of the carpus, notably the lunate onto the distal end of the ulna in those situations in which the distal radius has been shortened leaving an ulnar positive variance.

Specific Dislocations

Wrist Dislocations and Instability

In a distal radius dislocation, the radius is dislocated in reference to the ulna. However, the standard terminology describes the position of the ulna in relation to the radius.

carpal instability dissociative (CID; Linsheid): a carpal collapse pattern due to a ligamentous disruption in the proximal carpal row (i.e., scapholunate lunotriquetral pattern).

carpal instability nondissociative (CIND): a carpal collapse pattern due to disruption of ligaments connecting the proximal and midcarpal row or due to other extrinsic factors (i.e., radial malunion; Dobyns).

Desault d.: involves the radiocarpal joint with dorsal displacement of carpus and ulnar styloid process.

dorsal intercalated segment instability (DISI): a zigzag collapse pattern seen best on the lateral views of the wrist. The lunate appears to send its distal face dorsally. This can occur as a result of displaced scaphoid fractures, scapholunate instability, a nondissociated carpal instability. Commonly, the lunate follows the triquetrum volarly without the scaphoid

to contract its movement. The capitulunate angle is greater than 20 degrees and the scapholunate angle is greater than 70 degrees when the wrist is held in neutral posture.

lumbrical plus finger: posttraumatic contracture of the lumbrical will cause a paradoxical extension of the PIP and DIP joints each time an attempt is made to flex the digits.

lunate d.: volar semilunar dislocation in the wrist; a type of dislocation often not recognized.

perilunate d.: involves all carpals, which are shifted posteriorly, leaving the lunate in proper position; may be associated with a scaphoid fracture, in which case it is termed a **transscaphoid perilunate d.** Rarely do other carpi dislocate singularly or in association with fractures about the wrist. Wrist instabilities may be associated with fractures but specifically relate to ligamentous instabilities of the carpal bones. A devastating injury in which all the connecting ligaments between the lunate and its surrounding carpal bones are severed. Commonly, the capitate sits dorsal to the lunate. The lunate may dislocate volarly as part of the spectrum.

transscaphoid perilunate dislocation: similar to the perilunate dislocation except that the stress lines extend through the body of the scaphoid itself rather than the scapholunate ligament. The radial styloid may be fractured as well.

volar flexed intercalated segment instability (VISI): a zigzag collapse pattern with the lunate distal face turned volarly. This is seen best on lateral x-rays of the wrist. These can follow triquetral lunate instability or nondissociated instability patterns. An average reduced scapholunate angle of over 35 degrees.

Hand Dislocations

Dislocation can occur at all the small joints of the hand. Dislocations at the carpometacarpal (CMC) and metacarpophalangeal (MCP) joints generally occur in a dorsal direction. Dislocations at the MCP joints can sometimes be reduced without surgery. Dislocations in the hand are often associated with intraarticular fractures. Fracture-dislocations often require surgical reduction and fixation to realign joint surfaces.

Bennett d.: lateral or dorsal displacement of the first CMC joint.

boutonnière deformity: flexion contracture of the proximal interphalangeal (PIP) joint that may progress to subluxation. Associated with hyperextension contracture of the distal interphalangeal (DIP) joint. Deformity begins with rupture of the extensor tendon insertion of the PIP joint and later becomes a fixed deformity.

carpal instability: partial or complete dislocations between individual wrist bones, causing a click-clunk with wrist movement. Most often occurs at the scapholunate joint but can occur at the triquetrolunate, midcarpal, and even the radiocarpal joint.

gamekeeper's thumb: a hyperabduction injury with partial subluxation and instability of the thumb MCP joint due to traumatic rupture of the ulnar collateral ligament. Commonly due to a ski-pole strap injury; **skier's thumb**.

Nail and Skin Disorders

acanthosis nigricans: dull, gray, friable nails with leukonychia; can be an external marker of an internal malignancy.

acquired digital fibrokeratoma: benign tumors of fibrous tissue usually found on the hands and feet. These are flesh-colored with thorn-like projections with a raised erythematous skin rash at the base. These are otherwise known as acrofibrokeratomas.

acrolentiginous melanoma: an unusual variant of melanomas found on palmar surface of the hand and nail apparatus.

beak deformity (hook nail): with amputation of the tip of the distal phalanx, the nail may grow over the edge of the finger. It is unsightly and occasionally painful.

Bowen's disease: the eponym given to intra-epidermal squamous cell carcinoma known as squamous cell carcinoma *in situ*.

chromonychia: color changes in the nail unit.

clubbing: an increase in the unguophalangeal angle of greater than 180 degrees with fibrovascular hyperplasia of the nail unit.

digital fibrokeratoma: a benign tumor of fibrous tissue origin occurring on the tips of the fingers.

Dupuytren's contracture (palmar fibromatosis):

inflammatory process of the palmar fascia, occasionally extending into the fingers, in which severe contractures and nodular proliferation (skin dimples) may result. There are three phases: proliferative (nodular), involutional, and resolved. In the resolved state, the remaining constricting tissue is referred to as bands.

epidermoid cyst: benign cyst composed of epidermal fragments that have been pushed to the deeper layers by minor trauma.

keratosis: premalignant lesions seen in sun-exposed fair skinned individuals causing skin atrophy and telangiectasias. If allowed to progress, it may become squamous cell carcinoma.

leukonychia: whitening of the nail plate.

macronychia: an unusually large or wide nail.

micronychia: small, short, or narrow nail.

nail horn: formation of a nail horn can be a complication of distal tip amputations in which a fragment of nail tissue grows a thin projection at the tip of the finger, which can be quite painful and requires complete excision of the nail-forming tissue.

onychalgia: nail unit pain.

onychitis: inflammation of the nail plate.

onychogryphosis: nail plate hypertrophy that is horn-like resulting from trauma; **onychogryposis**.

onycholysis: distal separation of the nail plate from the underlying nail bed.

onychomadesis: proximal separation of the nail plate from the nail matrix.

onychomycosis: fungal infection of the nail unit.

onychophagia: nail biting.

onychoptosis: loss of the nail plate.

onychorrhaxis: spontaneous longitudinal splitting of the nail plate.

pincer or trumpet nail deformity: a pathologic curling of the nail plate and nail bed with ingrowing of the nail plate into the nail folds and progressive pinching off of the soft tissue of the distal fingertips, which results in pain and deformity.

pitted nail: surface pits of nails less than 1 mm in diameter.

pterygium: scarring of the eponychial fold and the nail fold to the nail bed in nail trauma leading to functional and esthetic deformities such as absence

of nail
been as
vascular

racket nai
the dist

reedy ni
furrows

sclerodac
become

tip, whi
ous calc

scleroder
skin of

interph
ulcerati

spoon nai
sides.

subungua
the dis

causing
tion of

subungua
nail bec

of bloc
destroy

drilled

turtle-bac
convex

unguis in
watch cr

convex
nary os

Other Sp
aponeuro

commo
are ben

Bouchard
spurs i

necessa

carpal bc
dorsal

painful

flexor ori
donitis

muscle

of nail growth or splitting of the nail. This has also been associated with nail bed ischemia and collagen vascular disease.

racket nail: thumbnail shorter than it is wide. Usually, the distal ends of the fingers are also short.

reedy nail: fingernail marked by longitudinal furrows.

sclerodactyly: a scleroderma in which the fingers become thin and shiny with sclerotic skin at the tip, which is due to subcutaneous and intracutaneous calcinosis and diffused fibrosis of the collagen.

scleroderma: an autoimmune disease that causes the skin of the hands to become thin, tense, and shiny; interphalangeal joint stiffness, distal ischemic ulceration, and autoamputation are common.

spoon nail: a central depression of the nail with raised sides.

subungual exostosis: a bone spur emanating from the distal phalanx dorsally under the nail bed, causing pressure pain, necrosis, and possible infection of the nail bed.

subungual hematoma: usually posttraumatic with nail bed laceration under an intact nail. A collection of blood under the nail plate, under pressure, can destroy the nail bed unless decompressed by a hole drilled into the nail plate (i.e., a hot paper clip tip).

turtle-back nail: a distorted fingernail, being more convex than normal.

unguis incarnatus: ingrown nail.

watch crystal nail: a nail as broad as it is long and convex lengthwise and crosswise; seen in pulmonary osteoarthropathy.

Other Specific Terms

aponeurotic fibroma: fibrous lesions of the hands commonly seen in childhood and adolescence. They are benign but can be locally aggressive.

Bouchard node: thick nodular swelling due to bone spurs in the proximal interphalangeal joints, not necessarily associated with systemic arthritis.

carpal bossing: prominence seen particularly at the dorsal index carpometacarpal (CMC) joint; may be painful but usually causes no symptoms.

flexor origin syndrome (reverse tennis elbow): tendonitis of pronator teres and wrist and finger flexor muscle origin on medial epicondyle of elbow.

ganglion: a clear, viscid, fluid-filled sac found near the wrist joints or fingers, arising from capsuloligamentous structures; rarely associated with other diseases; most commonly found on dorsum of wrist.

glomus tumor: small vascular lesion that is usually very painful and associated with hypersensitivity to pressure or temperature; usually in fingertip.

hamartoma: unusual tumors of the peripheral nerves most commonly involving the median nerve of the hand. It starts as a slowly progressive swelling in the distal forearm of the palm; common symptoms of nerve compression may be present.

hand-foot syndrome: swelling in hands and feet as seen in sickle cell disease.

Heberden node: a thick nodular swelling due to bone spurs in the distal interphalangeal joints; not necessarily associated with systemic arthritis.

inclusion cyst: a noninfectious process following healing of laceration or puncture wound; germinal matrix of dermal growth, causing mass comprised of desquamated dermal cells.

Luck's classification of Dupuytren's disease into three phases: proliferative phase, involutional phase, and residual phase, based on the histologic behavior of Dupuytren's fibroblast.

mucous cyst: a misnomer; this is a ganglion of the distal interphalangeal joint, which makes a cyst under the skin in the eponychial area.

nodular fasciitis: an uncommon reactive lesion that may simulate a sarcoma usually seen on the volar surface of the forearm, usually a rapidly growing small nodule. This has been confused with fibrosarcoma or myxoid liposarcoma leading to over-treatment.

overlap syndrome: seen in scleroderma patients with associated findings characteristics of lupus, dermatomyositis, or rheumatoid arthritis.

Preiser disease: spontaneous loss of blood supply and collapse of scaphoid, usually seen in young adults.

Raynaud's disease: a condition characteristic of color changes in the tip of the fingers either blanching or cyanosis in both hands and may not be involved with vasospastic disease and not lead to ulceration of the fingertips.

Raynaud's phenomenon: a clinical sign describing intermittent color changes that occur after exposure

to cold or stress. A condition characteristic of color changes in the tip of the fingers either blanching or cyanosis in both hands and may not be involved with vasospastic disease and not lead to ulceration of the fingertips.

stenosing tenosynovitis: a bulbous swelling of the tendon, causing the tendon to catch as it passes through the pulley (the thick fibrous tunnel that holds the tendon in place); sometimes caused by rheumatoid arthritis; **trigger fingers, snapping tendons.**

Infections

The hand has many structures that are vulnerable to infections. When edema and swelling place pressure on muscles, tendons, blood vessels, and nerves, function is disrupted and compartmental ischemia could result. Adhesions or fibrosis following infection may reduce hand function temporarily or permanently. Terms related to infections are the following.

barber's intradigital pilonidal sinus: a foreign body granuloma usually due to a reaction to hair implanted in the intradigital skin of the hand, first described in barbers.

collar-button abscess: a digital webspace infection usually in the subdermal fatty layers. Drainage is usually required; **shirt-stud abscess.**

dactylitis: nonsuppurative insidious chronic infections of the hands and fingers commonly seen in syphilis and tuberculosis.

deep space infection (palmar space infection): refers to infection of the thenar or midpalmar spaces.

ecthyma contagiosum: a chronic infection causing large tumor-like lesions in immunodeficient host; believed to be contracted from exposure to sheep and goats.

epidermoid cyst: benign cyst composed of epidermal fragments that have been pushed to the deeper layers by minor trauma.

eponychia: a nail-fold infection involving the entire eponychial fold and lateral nail fold. These are relatively rare.

fasciitis: a rapidly advancing necrotizing infection affecting the skin and subcutaneous tissue sparing the underlying muscle associated with high

morbidity and mortality, seen commonly in group A *streptococcus* infections.

felon: a subcutaneous abscess involving the tissue of the distal fingertip. These may be under great pressure and require drainage, usually through a midlateral approach.

Hansen disease (leprosy): commonly involves the hands; caused by *Mycobacterium leprae*. Peripheral neuropathy predominates with intrinsic atrophy and clawing. Later, soft tissue necrosis can result in actual loss of digits.

herpetic whitlow: a fascicular outbreak with an erythematous rim seen usually in fingertips of health care workers. These are commonly misdiagnosed and mistakenly drained. Supportive treatment is the mainstay. These are usually self-limited.

hockey-stick incisions: incisions placed at the lateral and distal aspects of the finger to facilitate drainage of felons (abscesses) of the fingertips.

horseshoe abscess: in those hands in which thenar and hypothenar spaces are interconnected, an abscess may spread to both sides of the hand in the shape of a horseshoe. Palmar space infection usually results from a penetrating wound. The deep spaces of the hand may fill with purulent material. Drainage is the key.

interdigital granuloma: small pyogenic granulomas found in the hand of cow milkers due to penetration of bovine hairs into the skin of the hand causing a foreign body reaction.

interdigital pilonidal sinus: see barber's interdigital pilonidal sinus.

Kanavel's sign: for pyogenic flexor tenosynovitis; there is a flexed position of the finger, symmetrical enlargement of the finger, excessive tenderness over the course of the tendon sheath, and extreme pain on passive extension of the digit.

Meleney infection: life- or limb-threatening infection with anaerobic bacteria or microaerophilic streptococcus. Amputation is usually required to save the patient's life; **gas gangrene.**

paronychia: infection in the soft tissue folds around the nail that usually results from injection of *Staphylococcus aureus* by a sliver of nail tissue, a manicure instrument, or a tooth. Drainage is mandatory.

pyogenic flexor tenosynovitis: a closed space infection of the flexor tendon sheath of the fingers and

thumb &
Streptoco
vel's sig
fingers,
digit, ex
tendon
extending
pyogenic
over the
caused b
complete
shooter's
drug abu
forearm.
subungual
plate or
tenosynovi
Causes a
matoid a
verruca vul
tissue. A

Surgery

Surgical pro
commonly
All terms, i
the goals of

Arthrodes
chevron a.:

geal (IP)
ting of t
resection

interphalar

metacarp
(IP) fusi
and rota
been pre

Moberg d
arthrode:

nonunio
squared l

Potenza a.:
from the

thumb generally caused by *Staphylococcus aureus*, *Streptococcus*, or *Pasteurella* presented with Kanavel's signs, which are semiflexed position of the fingers, symmetrical enlargement of the whole digit, excessive tenderness limited to the flexor tendon sheath, and excruciating pain on passively extending the finger.

pyogenic granuloma: an exophytic friable growth over the surface of the skin. These are usually caused by *Staphylococcus aureus* and will require complete excision to effect a cure.

shooter's abscess: infections caused by parenteral drug abuse involving accessible sites on the hand and forearm. These appear as raised ulcers with cellulitis.

subungual abscess: a collection of pus under the nail plate or over the nail bed.

tenosynovitis: inflammation of the tendon sheath. Causes are multifactorial and include overuse, rheumatoid arthritis, infection, and nonspecific onset.

verruca vulgaris: a viral wart involving the nail or skin tissue. A carbon dioxide laser is usually curative.

Surgery of the Hand and Wrist

Surgical procedures of the hand and wrist are more commonly described anatomically than by eponyms. All terms, including eponyms, are listed according to the goals of the surgical procedure.

Arthrodeses of the Fingers

chevron a.: a rigid stable construction for interphalangeal (IP) joint fusion; a precise, chevron-shaped fitting of the bone cuts of the joint to be fused with resection of the joint surface.

interphalangeal a.: cup and cone technique useful for metacarpophalangeal (MCP) or interphalangeal (IP) fusion, allows for fine adjustment of angles and rotatory alignment after joint surfaces have been prepared.

Moberg dowel graft: for an interphalangeal (IP) arthrodesis in which there has been bone loss or nonunion. A finger joint fusion using a small squared bone peg.

Potenza a.: a finger joint fusion using bone peg taken from the adjacent phalanx or metacarpal.

trapeziometacarpal fusion: for advanced trapeziometacarpal disease in the thumb in young, active patients.

Arthrodeses of the Wrist

Haddad-Riordan technique: a wrist arthrodesis using a radial approach and an iliac crest strut graft.

intercarpal a.: for wrist instability or collapse patterns, Kienboeck disease, rheumatoid arthritis, localized degenerative changes in the carpus. These include triscaphe (scaphotrapeziotrapezoid), scaphocapitate, capitulate, scapholunate, lunatotriquetral capitolunate (four-poster fusion). Moberg dowel grafts are useful in securing these fusions.

radiocarpal a.: commonly a total wrist fusion with or without autogenous graft. Useful for (1) a heavy laborer with posttraumatic arthritis, (2) failed radiocarpal arthroplasty, (3) rheumatoid arthritis, (4) tetraplegia with deformity of the wrist, and (5) tendon transfer surgery to stabilize the wrist.

radioulnar fusion: for the creation of a one-bone forearm for advanced disease of the distal radioulnar joint.

SLAC procedure (scapholunate advanced collapse): for the common combination of radioscapoid and midcarpal arthritis often seen in chronic nonunions of the scaphoid; a midcarpal arthrodesis with excision of scaphoid.

total wrist a.: fusion of the distal radius and proximal and distal carpal rows. Useful salvage procedure for severe carpal arthritis.

triscaphe a.: of the scaphotrapeziotrapezoid (SST) articulation. Useful in localized arthritis and for rotatory subluxation of the scaphoid.

Arthrodeses of the Wrist (Eponyms)

Abbott a.: using only cortical bone grafts; Abbott-Saunders-Bost a.

Brockman-Nissen a.: intra-articular wrist fusion.

Carroll a.: rabbit ear-shaped bone graft fusion.

Feldon 2-pin wrist arthrodesis: a technique for fusing the wrist in rheumatoid patients using two thin Steinman pins inserted through the second and third webspaces between the metacarpal bones across the carpus and the intermedullary canal of the radius.

Gill-Stein a.: extra-articular fusion using the dorsal distal radius as the graft; **radiocarpal a.**

Haddad-Riordan a.: intra-articular fusion using iliac crest bone graft.

Liebolt a.: fusion using chips of bone graft.

Nalebuff a.: fusion that includes use of a Steinmann pin.

Seddon a.: intra-articular fusion involving resection of the distal ulna.

Smith-Petersen a.: fusion that includes resection of the distal ulna.

Wickstrom a.: fusion of the wrist using bone graft inserted into both the radius and carpus.

Arthroplasties

An arthroplasty is the reconstruction of joints to restore motion and stability. It involves the metacarpophalangeal (MCP), carpometacarpal (CMC), and proximal interphalangeal (PIP) joints of the fingers and wrist, often with implants. The hand specialist frequently treats joint destruction commonly found in rheumatoid arthritis.

An implant arthroplasty involves a prosthetic replacement of joints by metallic or silicone-rubber parts, usually for arthritic conditions or traumatic ankylosis. Swanson silicone-rubber arthroplasty is a popular choice. Other prosthetic devices for the hand and wrist are the AMC total wrist (Volz, Steffe, Swanson).

anchovy procedure (Carroll): rolled palmaris longus (PL) graft placed into the space that remains after trapezium excision for pantrapezial arthritis.

Blatt capsulodesis: dynamic rotatory subluxation of the scaphoid. A proximally-based flap of dorsal wrist capsule is attached to the distal pole of the scaphoid; this will prevent downward movement of the distal pole during radial deviation of the wrist; **dorsal capsulodesis.**

capsulectomy: proximal interphalangeal (PIP) joint flexion contractures unresponsive to conservative treatment; proximal release of the joint capsule (volar plate) will improve movement.

Carroll (Froimson) a.: an interposition rolled tendon (palmaris longus [PL]) used as a spacer when the trapezium is removed for pantrapezial arthritis.

Darrach resection: resection of the distal 1 to 1.5 cm of distal ulna at the wrist. Once considered as the

standard procedure for the treatment of a myriad of distal radioulnar joint problems; now useful primarily in the elderly and for severe rheumatoid arthritis. (Albright and Chase.)

dorsal capsulectomy: the removal of the dorsal joint capsule; for example, in the treatment of distal radial ulnar joint fracture.

Eaton volar plate a.: a chronic subluxation of the proximal interphalangeal (PIP) joint after a displaced large volar lip fracture of the proximal end of the middle phalanx, greater than 50% of the articular surface. If left untreated, a chronic subluxation results. The volar plate is then advanced into the fracture site and tightened to prevent subluxation.

flexible hinge implant: a design for silastic implant arthroplasty developed by Swanson used in MP and PIP arthroplasties.

Fowler metacarpophalangeal (MCP) a.: for arthritis of the MCP joint. The metacarpal is cut in the form of a chevron at the base of the proximal phalanx and then cut into a V shape, with an interposition of extensor tendon fusion.

hemiresection interposition arthroplasty (Bowers): for distal radioulnar joint arthritis, resection of the articular surface of the distal ulna and interposition of a rolled tendon graft.

matched ulnar resection: popularized by Watson; resection of the articular surface of the distal ulna to match the shape of the radial styloid notch. This is useful for the treatment of distal radioulnar joint instability and arthritis.

Neibauer prosthesis: silicone hinge joints with built-in ties; useful in metacarpophalangeal (MCP) joint arthroplasty.

perichondral autografts: use of osteocartilaginous grafts (from ribs) to resurface the injured articular surface of a small joint in the hand.

proximal row carpectomy: a salvage procedure whereby the scaphoid, lunate, and triquetrum are excised. This is useful in treating advanced arthritis involving the radiocarpal joint if wrist motion is still desired by the patient.

radial styloidectomy: excision of the tip of the radial styloid; useful in isolated radioscapoid arthritis or as part of the SLAC wrist reconstruction.

Steffe thumb
thesis us
arthropl

Suave Kap
the artic
with pro
of appro

suspensio
ziometac
and plac
(FCR) as
An impro

Swanson i
all digit
arthropl
is most u
structur
use in th
concerns

Swanson p
carpoph
geal (PI
selected
useful (i.
arthropl
silicone :

trapezial h
half of t
joint; us

Tupper a.
arthritis,
sitional r

Vainio met
arthropl
tendon :

Voltz a.: a
arthropl
degenera

Zancholli c.
the meta
to treat

Zancholli-L.
digitou
band or
sion and

Stefee thumb a.: a cemented metal polyethylene prosthesis useful in thumb metacarpophalangeal (MCP) arthroplasty.

Suave Kapanje (Lauenstein procedure): fusion of the articular surface of the distal radioulnar joint with proximal resection of a distal ulnar segment of approximately 1.5 cm to facilitate motion.

suspensionplasty (LRTI-Burton): for advanced trapeziometacarpal arthritis, removal of the trapezium, and placement of half of the flexor carpi radialis (FCR) as an anchor to the metacarpal and as a spacer. An improvement on the classic "anchovy" procedure.

Swanson a.: complete array of silicone implants for all digital articula, joints, carpal bones, total wrist arthroplasty, distal ulna, and proximal radius. This is most useful in rheumatoid arthritis for the reconstruction of metacarpophalangeal (MCP) joints. Its use in the carpus had to be discontinued because of concerns regarding silicone synovitis.

Swanson prosthesis (silicone): most useful for metacarpophalangeal (MCP) and proximal interphalangeal (PIP) arthroplasty in rheumatoid arthritis. In selected situations, a total wrist arthroplasty is useful (i.e., in bilateral involvement). Carpal silicone arthroplasty is now falling out of favor because of silicone synovitis.

trapezial hemiarthroplasty: resection of the distal half of the trapezium, sparing the scaphotrapezial joint; useful for trapeziometacarpal arthritis.

Tupper a.: in metacarpophalangeal (MCP) joint arthritis, the volar plate may be used as an interpositional material after excision arthroplasty.

Vainio metaphalangeal (MP): MCP joint resectional arthroplasty with interposition of the extensor tendon and collateral ligaments.

Voltz a.: a metal-polyethylene cemented total wrist arthroplasty useful in selected cases of end-stage degenerative or rheumatoid arthritis.

Zancholli capsuloplasty: a volar plate advancement of the metacarpophalangeal (MCP) joint of the thumb to treat congenital hyperextension.

Zancholli-Lasso procedure: transfer of the flexor digitorum sublimus tendon (FDS) to the lateral band or the A2 pulley to prevent MP hyperextension and clawing; found in low ulnar nerve palsy.

Zancholli static-lock procedure: a volar plate advancement (plication) for the treatment of MP hyperextension; seen in claw deformities in low ulnar nerve palsy.

Neurologic Procedures

cable nerve grafts: a method of uniting strands of nerve graft and interposing them into a gap to repair a polyfascicular nerve discontinuity (of historic interest).

epineural repair: repair of lacerated nerve segments by repairing the epineurium. This is useful in digital nerves or in oligofascicular proximal nerves.

epineurotomy: the opening of the epineurium during a neurolysis procedure. This can be useful in certain cases of chronic nerve compression.

funiclectomy: for chronic end neuromas; peeling back the epineurium and resecting nerve fascicles, with reclosure and ligation of the epineurium. May aid in the treatment of end neuromas.

group fascicular repair: a perineural repair; useful in treating laceration of mixed motor and sensory nerves. Presumably, exact anatomic reapproximation will facilitate maximal functional return.

hemi-pulp flap: neurosensory free flaps from the great or second toe indicated for large single pulp defect. This is indicated when sensory function is essential for proper hand function and protection. This is best indicated for thumb reconstruction.

hetero-digital flaps: a cross-finger flap of dorsal skin to cover a significant palmar surface defect in an adjacent defect. Digital island transfer of pedicle flaps that are lifted with its neurovascular bundle and transferred to a defect on an adjacent digit.

internal neurolysis: presumably, internal dissection of intraneural scarring will facilitate return of nerve function. Originally thought to be useful in the treatment of carpal tunnel syndrome but now found to be harmful in many cases. This technique, however, is useful in the removal of intraneural neurilemmoma.

medial epicondylectomy: one method to decompress the ulnar nerve in the cubital tunnel by removing its bony floor, the medial epicondyle of the distal humerus.

Moberg procedure (key pinch): for tetraplegia; to restore the ability of key pinch in group II or III level tetraplegia. This includes carpometacarpal (CMC) thumb arthrodesis, extensor pollicis longus (EPL) tenodesis, and flexor pollicis longus (FPL) tenodesis or transfer.

neurectomy: the resection of a portion of nerve of an end neuroma (and presumed buried in bone or muscle).

neurotization: in patients with a profound brachial plexus injury with a flare anesthetic arm, the use of a live intercostal nerve grafted to a distal neural segment of the brachial plexus has restored some upper extremity function in select patients.

Trauma Procedures

Bentzon procedure: attempt to convert a painful scaphoid nonunion to a painless pseudarthrosis by soft tissue (capsular flap) interposition; of historic interest.

Bevin Aurglass technique: a digital web-deepening procedure for the correction of burn syndactyly.

distal finger amputation revision: procedure performed following traumatic amputation involving the distal phalanx (fingertip) by the following techniques:

finger flaps: to preserve sensation.

Atosoy: volar single V-Y advancement.

cross-finger flap: a section of skin with its blood supply intact from a neighboring finger used to cover open area.

Kutler: lateral double V-Y advancement.

thenar flap: one raised from the thumb side of the base of the palm.

Wolfe graft: free skin (pinch) graft; a section of full-thickness skin placed on the open area.

Fisk-Fernandez volar wedge: anterior cortical cancellous bone graft for the correction of scaphoid nonunion or malunion.

Gibraiel flap: a form of rotational skin flap using moving skin from the lateral aspect of the digit to the flexor surface with little or no movement of the pivot point.

Herbert screw osteosynthesis: the use of a dumbbell-shaped bone screw with variable pitch to affect rigid compressive internal fixation of a scaphoid

fracture or nonunion. This can be used with or without bone graft.

Kapandji fixation: for distal radius fracture; use of two K-wires inserted at 90 degrees at fracture site lateral and posterior and then angled 45 degrees anteriorly.

metacarpal lengthening (Matev): useful for irretrievable thumb amputation at the metacarpophalangeal (MCP) joint level; metacarpal osteotomy, application of a distraction device, slow distraction, and later bone grafting will partially restore length of the thumb ray. Secondary first web deepening may be required.

Russe bone graft: for scaphoid nonunion fracture; cortical cancellous graft placed by a volar approach through a longitudinal trough in the volar surface of the scaphoid that will enhance bony union.

Microvascular Procedures

anastomosis: term used for the direct repair of nerves and blood vessels.

back wall first technique: a microsurgical procedure in which the vessel wall away from the surgeon is sutured first, most useful in vessels approximately equal size when one or both of the presenting ends cannot be rotated within a double clamp.

Chinese flap (radial forearm flap): a radial forearm rotation flap based on the radial artery to repair radial and hand defects.

cross-arm flaps: random flaps using tissue from random pedicle flap using tissue from the patient's upper arm to cover a large defect on the patient's contralateral hand.

denervation: the accidental or intentional removal of sensory or motor nerve input to a distal site in the hand or arm.

dorsalis pedis flap: a microvascular free flap using the dorsalis pedis artery of the foot as the donor artery used to cover small defects in the upper extremity.

fibrin clot glue: a method of augmenting nerve apposition by using fibrin clot glue to "cement" the suture line.

flipping technique: used in microsurgery repairing a small vessel that is freely mobile. One can flip the vessel and over end to repair the back wall. Used in vein grafting and free-tissue transfer technique.

four-flap Z-
in the re

free flaps:
muscle, c
ferred us
anastome

interpositio
vascular
microana

laser Doppl
microvas
of the re
the prob

lateral arm
radial co
full-thick

no reflow
with arte
vascular
the field

sympathect
blood fl
sympath
chronic

toe-thumb
its full
and bor
or thum
cient ha

wraparound
great to
from th
at the t
reattach

donor s

Congenit
Barsky ma

the dist
on to t
shorten
tion of

interpha
Bilhaut-Cl
duplicat
thumb

four-flap Z-plasty: a double Z plasty used commonly in the reconstruction of the first webspace.

free flaps: a method of free tissue transfer using skin, muscle, or bone or all of the above. Tissue is transferred using its vascular pedicle and microsurgical anastomotic technique.

interposition graft: generally used for either nerve or vascular (vein) grafts to bridge a gap for direct microanastomosis of nerves and vessels.

laser Doppler fluximetry: this evaluates cutaneous microvascular perfusion. This evaluates the motion of the red blood cells in the area directly beneath the probe.

lateral arm flap: a free flap based on the posterior radial collateral artery; useful for covering large, full-thickness defects in the dorsum of the hand.

no reflow phenomenon: a microvascular anastomosis with arterial anastomosis. Disruption of the neurovascular tree may result in no venous return into the field.

sympathectomy: a method to improve peripheral blood flow by ablating the central or peripheral sympathetic innervation to arteries in treatment of chronic regional pain syndrome by surgery.

toe-thumb transfer: complete transfer of a toe with its full complement of neurovascular, tendinous, and bone structures to the hand to add to a digit or thumb on a posttraumatic or congenitally deficient hand.

wraparound procedure: the medial aspect of the great toe with its neurovascular bundles is removed from the toe and wrapped around a free bone graft at the tip of an amputation stump. This is then reattached using microvascular techniques. The donor site is secondarily grafted to close its defect.

Congenital Deformity Repairs

Barsky macrodactyly reduction: (1) filleting out of the distal phalanx, then placing all distal structures on to the end of the middle phalanx (this will shorten the macrodactylous digit); (2) hemiresection of the middle phalanx and primary distal interphalangeal (DIP) joint fusion.

Bilhaut-Cloquet procedure: for Wassel II thumb duplication (bifid thumb). The narrow half of each thumb tip is united with the other, discarding the

central units and allowing the thumb to become one phalanx.

Bonola technique: a dorsally based closing wedge osteotomy of the distal phalanx to correct a Kirner deformity.

Bracket resection: epiphyseal resection of the apex of a delta phalanx accompanied by fat grafting.

Carstan reverse wedge osteotomy: for the treatment of a delta phalanx; a central wedge is reversed and turned 180 degrees to straighten a digit.

callotasis: technique of one-stage bone lengthening by placement of an external fixator on both sides of osteotomy and stretching the bone out to lengthen short digits.

Cronin's technique: a technique for separating syndactylized digit using a combination of palmar and dorsal triangular flaps.

distraction lengthening: see *callotasis*.

Krukenberg procedure: in the congenital absence of a hand, the radius and ulna are surgically separated and covered with soft tissue so that the two bones will act as a claw.

physiolysis: the selective obliteration of the growth plate and area of uneven bone growth such as seen in Madelung's deformity. This is frequently accompanied by fat grafting to inhibit further bone growth.

radialization/centralization: an attempt to rebalance the hand and wrist on to the distal forearm in radial clubbed hand.

Skin, Nails, and Fascia Procedures

advancement flaps (Kleinert-Atosoy): called V-Y flaps; flaps cut either from the volar pad or from the radial and ulnar pad of the distal fingertip for the reconstruction of fingertip injuries with skin and subcutaneous loss.

axial cutaneous flaps (scapular flap): free or island flap on a subscapular artery pedicle for medium-sized defect coverage in the hand.

axial flag flaps: a rotational skin flap based on a dorsal digital artery used for digital skin and subcutaneous defects.

axial pattern skin flap: a long skin flap possible because of an underlying vascular supply running along its long axis underneath.

cocked-half flap (Gillies): reconstruction of a thumb amputation at the metacarpophalangeal (MCP) joint level with a local skin graft, iliac crest graft, and skin graft.

composite nail bed flap: a full-thickness nail bed graft from a toe to cover a defect in a finger nail bed.

cross-finger flap: the dorsal skin of one digit is flapped over itself to create coverage for a volar skin defect of an adjacent digit.

cryotherapy: a method of using extreme cold to freeze skin lesions such as actinic keratosis.

escharotomy: in the management of deep thermal burns, burned and contracted skin is incised to decompress deeper tissues and prevent further necrosis.

fasciectomy: generic term used to describe excision of the palmar fascia, usually when involved in Dupuytren's disease.

fasciotomy: (1) opening of muscle compartments and decompressing intrinsic muscle spaces in compartment syndrome; spaces to be decompressed are interosseus muscles (through dorsal incisions or volar thenar and hypotheran compartments); (2) incision into a Dupuytren's central cord to release contracture; this is useful in elderly and debilitated patients, but contracture recurrence is common.

flag flap: a rotational pedicle flap harvested on the dorsum of the finger and used to cover defects on adjacent fingers or over the metacarpophalangeal joint. The same can be performed as a volar flap as well.

Macindo procedure: a form of palmar fasciectomy for Dupuytren's contracture when the palmar skin is left open to granulate.

marsupialization: a technique used to expose the germinal matrix of a nail in patients with chronic paronychia in which a crescent of the eponychial fold is removed to uncover chronic fungal infection.

Moberg flap: useful in thumb tip reconstruction; the volar half of the thumb soft tissue is elevated with its neurovascular structures, and by flexing the interphalangeal (IP) joint of the thumb, the flap is then stretched over the thumb tip.

neurovascular island transfer: a method of transferring sensibility to an important part of the hand such

as the thumb tip from a less important part of the hand, whereby a portion of skin is left connected to its neurovascular structures and passed subcutaneously to a different part of the hand.

onychectomy: removal of a fingernail.

onychotomy: the method of cutting into a nail, usually to remove a mass under the nail.

pedicle flap: a procedure that permits an island of skin and subcutaneous tissue to be transferred from one place to another on its own vascular supply, using multiple operative stages.

pedicle grafts: a term used for pedicle flaps but also includes *pedicle bone grafts*. *Island pedicle grafts* and *neurovascular pedicle grafts* are pedicle, skin, or subcutaneous tissue containing blood and nerve supply, thus providing sensation for the skin graft.

thenar flap (Smith-Albin): for fingertip coverage, an H flap is raised on the thenar eminence and the digit tip is flexed down to it. By 10 to 14 days, the flap provides a good skin and soft tissue coverage to the distal digit tip. However, digital stiffness is common.

Muscle and Tendon Surgery of the Hand

There are two types of tendon procedures: (1) restoration of tendon function by direct repair of a tendon, its advancement, or its transfer and (2) freeing of tendon from scar tissue, restrictive bands, or abnormal lining tissues. Because of these basic categories, tendon grafts and advancement procedures are listed here contextually and not in alphabetic order.

Aichef technique: a method of central SLIP reconstruction in Boutonnière deformity by designing a tendon flap using the central half of the lateral bands and bringing them toward the midline to recreate a central SLIP in which the central SLIP has been irreparably damaged due to trauma.

Bateman's procedure: indicated in axillary and supra-scapular nerve palsy, which involves an acromial fragment to the humerus to facilitate shoulder abduction.

Brent-Moberg tenodesis: thumb flexor tenodesis to restore key pinch in quadriplegics. A technique using flexor or extensor tendon graft to restore and treat functions in ulnar nerve palsy.

Burkhalter

the proxi-
geal flex-
deformit-

deltoid flap

cover sma-

Hammond'

for recor-
chial ple-
of the d-
and fron-
of the tr-
the later-
abductio-
major te-

House reci-

tions to
varying-
dependu-
spine.

Hui-Linschi

designed
ment usi-
ularly u-
secondar-

Lasso pro-

tenodesi-
joint us-
with hy-
phalang-
proxima-

Lennox F

motorec-
rect clav-
geal flex-

Littler-Eatr

stabilizi-
stage I I

Littler's bc

transpo-
central :

Mennen's

longus
brane to
out alo-

Burkhalter transfer: threading digital flexors through the proximal phalanx to facilitate metacarpophalangeal flexion in low ulnar nerve palsy with claw deformities.

deltoid flap: a muscular-free flap using the deltoid to cover small to moderate deficits in the upper extremity.

Hammond's procedure: multiple muscle transfers for reconstruction of the paralyzed shoulder in brachial plexus injuries. Transfer of the posterior third of the deltoid to the lateral aspect of the clavicle and from the tendinous origins of the long head of the triceps and the short head of the biceps to the lateral aspect of the acromion to aid in shoulder abduction. Transfer of the latissimus dorsi to teres major tendons.

House reconstruction: complete array of reconstructions to facilitate hand function in patients with varying degrees of quadriplegia (tetraplegia) depending on the level of the lesion in the cervical spine.

Hui-Linscheid procedure: a tenodesis procedure designed to reconstruct the volar ulnar carpal ligament using a strip of flexor carpi ulnaris tendon particularly useful in primary ulnar-carpal instability or secondary distal radial ulnar joint instability.

Lasso procedure: flexor digitorum superficialis in a tenodesis mode to flex the metacarpophalangeal joint used commonly in tetraplegia and patients with hyperextension deformities of the metacarpophalangeal joint and with hyperextension of the proximal interphalangeal joint.

Lennox Fritsch technique: a palmaris longus motored four-tail transfer used in ulnar palsy to correct claw deformities to promote metacarpophalangeal flexion and proximal interphalangeal extension.

Littler-Eaton ligament reconstruction: method of stabilizing the base of the thumb metacarpal in stage I basal joint arthritis.

Littler's boutonnière reconstruction: includes dorsal transposition of the lateral bands and repair of the central SLIP to the base of the middle phalanx.

Mennen's opponensplasty: the extensor pollicis longus is passed through the interosseous membrane to the volar aspect of the forearm and backed out along the thenar eminence to the dorsal surface

of the metacarpophalangeal joint, thus creating opponens function.

Parke's tenodesis: static tenodesis using wrist extensors as "grafts" to treat claw deformities to promote MP flexion.

Ranney's technique: an extensor digiti minimi transfer to the neck of the fifth metacarpal to restore the transverse metacarpal arch in ulnar nerve palsy.

Riordan's technique: a flexor carpi radialis transfer using a free graft passing from the flexor to the extensor side of the forearm, radial lateral bands of the fingers involved in claw deformity in low ulnar nerve palsy.

tendolysis: often called tenolysis; a tendon release. It describes two different types of procedures: (1) one in which the tendon is freed from scar tissue or entrapment so that it may move properly and (2) tenosynovectomy, whereby all or part of the sheath of a functioning tendon is excised.

tendon advancement: done when the damage segment of a tendon is so near its insertion that a direct tendon-to-bone rather than tendon-to-tendon repair is necessary. One such technique is the **Wagner** advancement of the profundus tendon.

tenosynovectomy: a procedure whereby the tenosynovium surrounding the tendon sheaths are removed such as in rheumatoid arthritis to prevent tendon rupture or to treat tendon entrapment.

tenodesis: the fixation of a tendon onto two bony locations to keep a joint from flexing or extending beyond a selected range. This procedure lends itself to prevention of hyperextension of the metacarpophalangeal joints in ulnar claw deformity. Two commonly done are the **Fowler** and **Riordan** procedures.

tenorrhaphy: the repair of a lacerated tendon, either immediate or delayed.

tenotomy: a procedure in which a tendon, either flexor or extensor, is sectioned purposely to correct a deformity to bring back the position or function of the hand or wrist.

Tendon Repair Techniques

Numerous techniques and types of sutures are used in repairing tendons. A tendon repair is any reapproximation of a partially or completely severed tendon. The

specific technique is directed at gaining maximal strength with minimal scarring.

Becker: multiple cross-stitching technique for approximation of fresh tendon edges.

Bunnell opponensplasty: the use of the flexor digitorum sublimis IV as a donor motor for thumb opposition using the pulley in the region of the flexor carpi ulnaris and the pisiform.

Kleinert: modification of Bunnell technique, burying suture knot at tendon edge.

modified Kessler suture: a direct end-to-end grafting suture for flexor tendon lacerations, especially in zone II. These are usually augmented with epitendinous sutures.

Pulver-Taft weave: the strongest method of reattaching two tendons where space is not at a premium. It involves weaving tendon ends in and out of each other.

Tsuge: multiple cross-stitching technique for tendon reapproximation.

Verdan: multiple cross-stitching technique for tendon reapproximation.

Other specific techniques include **Tajima**, **Halsted**, **Salvage**, and **Silfverskiöld** procedures.

Tendon Grafts and Transfers

A tendon transfer is the relocation of a tendon from one place to another. The tendon retains attachment to its muscle. By contrast, free tendon graft requires complete excision of a tendon and its repositioning in a new location. Tendon transfers may be static or dynamic.

central slip repair/reconstruction: procedure designed to repair the common extensor insertion into the proximal dorsal end of the middle phalanx, thus restoring active proximal interphalangeal (PIP) extension.

Clark pectoralis major transfer: transfer of the sternocostal portion of the pectoralis major muscle for the restoration of elbow flexion in brachial plexus injury.

crossed intrinsic transfer: in rheumatoid arthritis, with ulnar deviation of the digits at the metaphalangeal joint, a conjoined ulnar intrinsic tendon is

released from one digit and placed into the radial conjoined intrinsic tendon of the adjacent digit on its ulnar side.

Green transfer: flexor carpi ulnaris (FCU) to extensor carpi radialis brevis (ECRB) transfer to correct a wrist flexion deformity in cerebral palsy. Overcorrection is common.

Jones transfer: in radial nerve palsy, tendon transfer designed to restore thumb, digital, and wrist extension.

flexor pronator slide: release of the flexor pronator muscle group origin allowing the muscle to slide distally. This helps correct wrist and digital flexion deformity and forearm pronation deformity in cerebral palsy.

flexor tenolysis: method used to free flexor tendon from its surrounding scars approximately 4 months after flexor tendon repair with secondary tendon adherence.

Fowler tenodesis: static tendon grafts originating in the extensor retinaculum, passing volarly to the deep transverse metacarpal ligament, and inserting it into the radial lateral bands. A procedure to prevent hyperextension of the metacarpophalangeal (MCP) joint as seen in the claw deformity of low ulnar nerve palsy.

tenovagiotomy: procedure designed to release stenosing tenosynovitis by incising a retinaculum or flexor pulley.

static tendon transfer: transfer of a free tendon graft that is attached to two or more bony locations such that the active movement of one joint will cause the passive movement of some other joint. For example, a tendon appropriately inserted proximal to the wrist and in the fingers will cause flexion of the fingers if the wrist is extended.

dynamic tendon transfer: one that brings about motion by direct action of muscle contraction.

Tendon transfers are commonly required to replace or assist voluntary muscle function that is lost because of nerve injury, nerve disease, or direct and indirect sequelae of trauma to the muscle. Substantial numbers of transfers are used in central nervous system paralyses such as those caused by strokes and polio. Transfers are listed by categories that define function.

Camitz p

attach

emine

base o

as an

carpal

finger ex

finger fle

joint (

Stiles-J

dures,

Huber tr

thumb

thenar

is, a ne

opponen

extrins

opposi

Burkha

Miller,

Steindler

causing

chialis)

the flex

of the

proxim

thumb at

of the

thumb ad

finger;

Royle-

wrist ext

teres to

Tenosyn

Tenosyno

tendon sh

commonly

rheumatoi

the follow

abductor

fibrous

longus

syndroi

called c

Camitz procedure: the palmaris longus, with its distal attachment tubularized, is passed under the thenar eminence and attached to the radial aspect of the base of the proximal phalanx of the thumb to act as an opponensplasty. This is useful in chronic carpal tunnel syndrome.

finger extension: Boyes procedure.

finger flexion: for flexion of the metacarpophalangeal joint (intrinsic transfer); Boyes, Fowler, Bunnell, Stiles-Bunnell, Riordan, and Pulver-Taft procedures, and Brand I and Brand II procedures.

Huber transfer: a procedure designed to restore thumb opposition based on a transfer into the thenar eminence of the abductor digiti minimi, that is, a neurovascular pedicle.

opponensplasty: the use of any of the intrinsic or extrinsic muscle tendon units to restore thumb opposition (i.e., in median nerve palsy); Brand, Burkhalter, Groves, Goldner, Riordan, Phalen-Miller, Littler, Huber, and Fowler procedures.

Steindler flexorplasty: in brachial plexus injury causing paralysis of elbow flexion (biceps and brachialis) with sparing of distal forearm musculature, the flexor pronator mass with the medial epicondyle of the distal humerus is transferred anteriorly and proximally on the humerus to effect elbow flexion.

thumb abduction: pulling thumb away from the side of the hand; Boyes procedure.

thumb adduction: pulling the thumb to side of index finger; Boyes, Bunnell, Edgerton-Grand, and Royle-Thompson procedures.

wrist extension: Boyes procedure, using pronator teres to the extensor carpi radialis brevis muscle.

Tenosynovectomy

Tenosynovectomy refers to the excision of thickened tendon sheath and other tissue surrounding a tendon, commonly seen in infection, chemical irritation, and rheumatoid arthritis (synovectomy). It also refers to the following two procedures in hand surgery.

abductor pollicis longus release: a release of the fibrous canal surrounding the abductor pollicis longus at the wrist for symptoms of de Quervain's syndrome (pain on abduction of the thumb). Also called *de Quervain's release*.

trigger finger release: a release of fibrous covering of tendon (pulley) at the base of the finger to prevent a tendon with nodular changes from snapping with motion of the finger. Also called *snapping tendon release*.

Other Tendon Procedures

boutonnière reconstruction: a classic extensor tendon reconstruction for boutonnière deformity, designed to restore active extension of the proximal interphalangeal (PIP) joint and to prevent its flexion posturing. This procedure is fraught with difficulty, and prognosis is guarded; Littler, Matev, Fowler procedures.

Hunter rod (active tendon implant): a silicone rubber tendon replacement that can function as a permanent tendon. This implant has a proximal loop that can be sewn into forearm motor muscles.

Kortzeborn procedure: a lengthening of the extensor tendons of the thumb and formation of a fascial attachment of the thumb to the ulnar side of the hand to relieve "ape hand" deformity.

passive tendon implant: a silicone-rubber tendon spacer or rod that is used to form a new synovium-filled channel. It is removed during a second-stage procedure, and a tendon graft that is threaded through. Useful as a two-stage procedure when the tendon bed is extremely scarred and a direct tendon graft is impossible.

swan-neck revision: surgery designed to eliminate a swan-neck deformity in the fingers by revision of tendons; Swanson revision, Littler modified tendon revision.

Other Hand and Wrist Procedures

capsular release (capsulectomy): an incision of a joint capsule done to regain lost motion caused by contractures.

capsulodesis: in hand surgery, the capsule, which may include the dorsal or volar plate, may be tightened to help hold an affected joint in a position that can no longer be held voluntarily. This is done often for nerve injuries and is commonly called the *Zancolli* procedure (for clawhand deformity); *volar capsular reefing*, *Blatt dorsal capsulodesis*.

carbon (pyrocarbon) implant: a new form of resurfacing arthroplasty for the metacarpophalangeal and proximal interphalangeal joints used commonly in osteoarthritis.

carpal tunnel release: a division of the strong ligamentous band (transverse carpal ligament) that covers the median nerve and flexor tendons of the finger and thumb. This is usually done to relieve pressure on the median nerve that may result from arthritis, trauma, or unknown causes. A *tenosynovectomy*, if necessary, may be done through the same incision.

carpectomy: the removal of the proximal row of carpal bones, usually indicated in some forms of arthritis or severe spastic contractures.

dermodesis: the removal of a segment of skin and then closure of the skin margins to shorten skin and restrict motion of a joint. It is frequently done in conjunction with a *Zancolli* capsulodesis for ulnar clawhand.

Dupuytren's contracture release: named after a French surgeon, this surgical procedure is the excision of the contracted fibrotic bands of the palmar fascia. However, the skin is often adherent and recurrent deformity is a problem. Specific techniques for resection of these bands are:

Luck procedure: percutaneous transection of fibrotic bands without removal of tissue.

McCash procedure: transverse skin incision with transection of bands and then passive stretch dressing applied, leaving the wounds open.

fishmouth incision: a wraparound incision over the distal end of the finger to facilitate drainage.

Foucher technique: a procedure for internal fixation of metacarpal neck fractures using multiple prebent Kirschner wires in a "wire-stacking technique."

ganglionectomy: the excision of a ganglion, which usually occurs on the dorsum of the wrist or the base of the fingers.

Hammond's procedure: multiple muscle transfers for reconstruction of the paralyzed shoulder in brachial plexus injuries. Transfer of the posterior third of the deltoid to the lateral aspect of the clavicle and from the tendinous origins of the long head of the triceps and the short head of the biceps to the lateral aspect of the acromion to aid in shoulder abduction. Transfer of the latissimus dorsi to teres major tendons.

infiltration technique: a method of axillary block for regional anesthesia in upper extremity surgery. The anesthetic is injected around the axillary artery inside the sheath of the neurovascular bundle spreading local anesthetic around the brachial plexus.

interscalene block: a brachial plexus block using a needle in the interscalene space to numb the brachial plexus to effect regional anesthetic commonly used in shoulder surgery.

island flaps: either pedicle or free flaps of small amounts of tissue either skin, bone, muscle, or a combination of both for the reconstruction of small area defects.

joint leveling procedures with ulnar lengthening and radial shortening: used to restore the anatomic relationship between the distal radius and distal ulna (generally, the ulnar variance seen on the contralateral "normal side").

kite flap: an island pedicle of flap proximally based on the first dorsal metacarpal artery designed on the radial side of the distal portion of the second metacarpal and metacarpophalangeal joint used to reconstruct defects on the dorsum of the hand usually on the radial side.

K-wire fixation: in a Kirschner wire (K-wire) fixation, small threaded or nonthreaded wires are used to transfix fractures or to produce traction with the use of an external appliance.

latissimus dorsi flap: a form of myocutaneous pedicle or free flap in which blood supply derives from the thoracodorsal artery and is used to cover large soft tissue defects.

mallet finger revision: designed to regain active extension of the distal interphalangeal joints of the finger.

Fowler release: technique used at the proximal interphalangeal joint for a mallet finger.

palmar advancement flaps: known as *the Moberg's flap*. A proximally based flap used to cover distal soft tissue defects; most commonly used in the thumbs.

palmar fasciectomy, fasciotomy: the release, with or without resection of tissues, of shortened, thickened, and contracted fasciae in the palm or finger in flexion deformities resulting from Dupuytren's contracture.

phalangectomy: the excision of a part or all of a phalanx because of trauma or arthritis. Rarely

perform
the foo
pollicizat
trauma
the ind
or func
Littler
random |
quadril
three o
vessels
RASL pro
pholun
of the
mentor
interna
transve
interca
ray ampu
and all
metaca
regional f
ately a
vicinity
depend
replantat
the rea
attemp
part su
revision
thumb
of speci
saphenou
saphen
small-
synovect
cedure
tendino-c
that ca
forearm
structic

performed in the hand, more commonly done in the foot.

pollicization: any operation replacing a congenitally or traumatically missing thumb by reconstruction of the index, long, ring, or little finger such that it acts or functions as a thumb; **Buck-Gramko, Riordan, Littler, Gillies, and Verdan procedures.**

random pattern flaps: skin flaps that are generally quadrilateral in shape and are raised by incising three of the four sides and it depends on the minute vessels of the subdermal and subcutaneous plexus.

RASL procedure: the reduction association of the scapholunate joint. This consists of an open reduction of the scapholunate articulation, repair of the ligamentous remnants, and protection of the repair by internally blocking the scapholunate joint with a transverse Herbert's screw for a year to provide intercarpal fibrosis.

ray amputation: a procedure to remove a metacarpal and all phalangeal segments of a finger distal to that metacarpal.

regional flaps: those derived from tissues not immediately adjacent to the primary defect but in its vicinity. They can be random or axial pattern flaps depending on their blood supply.

replantation: a microsurgical procedure that requires the reattachment of nerves, veins, and arteries to attempt restoration of function to a freshly severed part such as a finger.

revision polydactyly: polydactyly usually affects the thumb and little finger. Revision requires reattachment of specific tendons or ligaments; **Marks and Bayne.**

saphenous flap: a myocutaneous flap based on the saphenous artery and nerve. This is used to cover small- to medium-sized defects.

synovectomy: removal of synovium in joints. The procedure is done frequently for rheumatoid arthritis.

tendino-cutaneous flaps: vascularized tendon graft that can be transferred with a dorsalis pedis or radial forearm flap. This is indicated for one-stage reconstruction of degloving injury to the dorsum of the

hand with loss of skin and extensor tendons for example.

Tikhor-Linberg procedure: an alternative to the arm amputation of well-localized tumors around the shoulder, which represents a resection of the shoulder girdle with preservation of the arm.

transposition flaps: skin flaps used to cover small deficits. These may be axial pattern or random pattern.

trapeziectomy: removal of the trapezium bone in the treatment of basal joint arthritis, which may be done alone or in concert with an interposition arthroplasty.

ulnar forearm flap: a fascial cutaneous flap that is based on the ulnar artery and is harvested from the ulnar aspect of the forearm used to cover deficits of the ulnar side of the hand or used as a free flap for distal defect.

wafer procedure: for ulnar plus wrist; resection of the distal 2 to 3 mm of the ulnar head, leaving the styloid intact.

Approaches

Wrist

dorsal a.: on the back side of the wrist, this approach is used for tendon transfers, fusions, and ganglionectomies.

Henry approach: for volar forearm.

volar a.: approach from the palmar aspect of the wrist, used for carpal tunnel releases, tendon explorations, and some bony procedures.

medial a.: an approach to the ulnar side of the wrist used for some tendon transfers and for the Darrach procedure; **Smith-Petersen.**

lateral a.: used on the radial side of the wrist for tendon transfers, radial styloidectomy, and visualization of the navicular bone.

Hand

Surgical approaches are too numerous and complicated to describe here. Refer to Edmonson AS, Crenshaw AH, editors: *Campbell's Operative Orthopedics*, ed 9, vol 10, St Louis, 1996, Mosby.